



INDIANA UNIVERSITY

TRANSPORTATION RESEARCH CENTER

School of Public and Environmental Affairs
222 West Second Street
Bloomington, Indiana 47403-1501
(812) 855-3908 Fax: (812) 855-3537

REMOTE CHILD AIR BAG-RELATED FATALITY INVESTIGATION

CASE NUMBER - IN-03-025
LOCATION - Ohio
VEHICLE - 1996 FORD CONTOUR
CRASH DATE - July 2001

Submitted:
April 18, 2005
Revised:
July 28, 2007



Contract Number: DTNH22-01-C-07022

Prepared for:

U.S. Department of Transportation
National Highway Traffic Safety Administration
National Center for Statistics and Analysis
Washington, D.C. 20590-0003

DISCLAIMERS

This document is disseminated under the sponsorship of the Department of Transportation in the interest of information exchange. The United States Government assumes no responsibility for the contents or use thereof.

The opinions, findings, and conclusions expressed in this publication are those of the authors and not necessarily those of the National Highway Traffic Safety Administration.

The crash investigation process is an inexact science which requires that physical evidence such as skid marks, vehicular damage measurements, and occupant contact points be coupled with the investigator's expert knowledge and experience of vehicle dynamics and occupant kinematics in order to determine the pre-crash, crash, and post-crash movements of involved vehicles and occupants.

Because each crash is a unique sequence of events, generalized conclusions cannot be made concerning the crashworthiness performance of the involved vehicle(s) or their safety systems.

Technical Report Documentation Page

1. <i>Report No.</i> IN-03-025		2. <i>Government Accession No.</i>		3. <i>Recipient's Catalog No.</i>	
4. <i>Title and Subtitle</i> Remote Child Air Bag-Related Fatality Investigation Vehicle - 1996 Ford Contour Location - Ohio			5. <i>Report Date:</i> April 18, 2005		
			6. <i>Performing Organization Code</i>		
7. <i>Author(s)</i> Special Crash Investigations Team #2			8. <i>Performing Organization Report No.</i>		
9. <i>Performing Organization Name and Address</i> Transportation Research Center Indiana University 222 West Second Street Bloomington, Indiana 47403-1501			10. <i>Work Unit No. (TRAIS)</i>		
			11. <i>Contract or Grant No.</i> DTNH22-01-C-07002		
12. <i>Sponsoring Agency Name and Address</i> U.S. Department of Transportation (NRD-32) National Highway Traffic Safety Administration National Center for Statistics and Analysis Washington, D.C. 20590-0003			13. <i>Type of Report and Period Covered</i> Technical Report Crash Date: July 2001		
			14. <i>Sponsoring Agency Code</i>		
15. <i>Supplementary Notes</i> Remote investigation of a child air bag-related fatality traffic crash involving a 1996 Ford Contour, equipped with dual frontal air bags, and a 1996 Buick Regal					
16. <i>Abstract</i> This report covers a remote investigation of an air bag deployment crash involving a 1996 Ford Contour (case vehicle) and a 1996 Buick Regal (other vehicle). This crash is of special interest because the case vehicle's front right passenger (3-month-old male), who was in a rear-facing child safety seat, sustained fatal head injuries from the deploying front right passenger air bag. The case vehicle was traveling westward in the westbound left turn lane of a three-lane, undivided city street, approaching a four-leg intersection and intending to turn left. The other vehicle had been stopped, headed south, at the mouth of a commercial driveway on the north side of the same roadway, intending to cross the westbound lanes and turn left. The other vehicle's driver had exited the driveway, crossed the westbound through lane and was in the process of making the intended left turn. The case vehicle's front impacted the other vehicle's left front area, causing the case vehicle's driver and front right passenger air bags to deploy. The other vehicle was equipped with dual frontal air bags that did not deploy. Both vehicles came to rest near the point of impact in the left turn lane. The case vehicle was towed but not due to damage and the other vehicle was driven away. The deploying front right passenger's air bag struck the leading edge of the child seat. The force of the deploying air bag was transmitted to the child's head, causing: a skull vault fracture across the vertex and radiating outward to the left and right parietal bones, the frontal bone, and the anterior cranial fossa; massive cerebral edema; and other head and brain injuries. The case vehicle's safety-belted driver (36-year-old female) sustained minor injuries. Both the case vehicle's back right passenger (3-year-old male), who was in a forward-facing child safety seat, and the unrestrained back left passenger (34-year-old female) did not sustain any injuries.					
17. <i>Key Words</i> Air Bag Deployment			Motor Vehicle Traffic Crash Injury Severity		18. <i>Distribution Statement</i> General Public
19. <i>Security Classif. (of this report)</i> Unclassified	20. <i>Security Classif. (of this page)</i> Unclassified	21. <i>No. of Pages</i> 9	22. <i>Price</i> \$4,400		

TABLE OF CONTENTS

IN-03-025

	<u>Page No.</u>
BACKGROUND	1
CRASH CIRCUMSTANCES	1
CASE VEHICLE: 1996 FORD CONTOUR	1
AUTOMATIC RESTRAINT SYSTEM	3
CASE VEHICLE FRONT RIGHT PASSENGER'S KINEMATICS	3
FRONT RIGHT PASSENGER'S INJURIES	4
CASE VEHICLE DRIVER'S KINEMATICS	6
DRIVER'S INJURIES	6
CASE VEHICLE BACK LEFT PASSENGER'S KINEMATICS	6
CASE VEHICLE BACK RIGHT PASSENGER'S KINEMATICS	7
OTHER VEHICLE: 1996 BUICK REGAL	7
SCENE DIAGRAM	9
 SELECTED PHOTOGRAPHS	
Figure 1: Case vehicle's front, straight on view	2
Figure 2: Case vehicle's front left corner	2
Figure 3: Case vehicle's cracked windshield	2
Figure 4: Front right passenger air bag module's deformed cover flap	2
Figure 5: Driver's air bag	3
Figure 6: Front right passenger's air bag	3
Figure 7: Back right forward facing child safety seat	7
Figure 8: Other vehicle's left front corner area	8

This report was brought to the NHTSA's attention in 2003 through a review of the 2001 Fatality Analysis Reporting System (FARS) data. This crash involved a 1996 Ford Contour (case vehicle) and a 1996 Buick Regal (other vehicle). The crash occurred in July 2001, at 4:50 p.m., in Ohio, and was investigated by the applicable municipal police department. This crash is of special interest because the case vehicle's front right passenger (3-month-old male, white, unknown if Hispanic), who was in a rear-facing child safety seat, sustained fatal head injuries from the deploying front right passenger air bag. The safety-belted driver (36-year-old female, race/ethnicity unknown) sustained minor injuries. Both the case vehicle's back right passenger (3-year-old male, race/ethnicity unknown), who was in a forward-facing child safety seat, and the unrestrained back left passenger (34-year-old female, race/ethnicity unknown) did not sustain any injuries. This report is based on the police crash report, police photographs, the police criminal investigation pertaining to possible negligent homicide charges, medical treatment and autopsy data for the fatal victim, and this contractor's evaluation of the evidence.

CRASH CIRCUMSTANCES

The case vehicle was traveling westward in the westbound left turn lane of a three-lane, east/west, undivided city street, approaching a four-leg intersection and intending to turn left to travel south on the intersecting roadway (i.e., there was one through lane in both the east and westbound directions and a left turn lane for westbound traffic). The other vehicle had been stopped, headed south, at the mouth of a commercial driveway on the north side of the same roadway, intending to cross the westbound lanes and turn left to travel east on the east/west roadway. It was daylight, the weather was clear, the speed limit was 56 km.p.h. [35 m.p.h.] and the road surface was dry. Traffic in the westbound through lane had stopped to enable the driver of the other vehicle to make the intended left turn from the driveway. The other vehicle's driver had exited the driveway, crossed the westbound through lane and was in the process of making the intended left turn. The police estimated that the case vehicle was traveling 16 km.p.h. [10 m.p.h.] and the other vehicle was traveling 3 km.p.h. [2 m.p.h.]. Neither driver attempted any avoidance actions. The crash occurred in the westbound left turn lane (no scene photos available).

The case vehicle's front impacted the other vehicle's left front area, causing the case vehicle's driver and front right passenger air bags to deploy. The other vehicle was equipped with dual frontal air bags that did not deploy. Both vehicles came to rest near the point of impact in the left turn lane of the east/west roadway.

CASE VEHICLE

The case vehicle was a 1996 Ford Contour front wheel drive, four-door, five-passenger sedan (VIN: 3FALP66L2TM-----), equipped with a 2.5 liter V6 gasoline engine. Four wheel anti-lock brakes were an option on this model, but it is unknown if the case vehicle was so equipped. The case vehicle was fitted with manual, three-point, lap-and-shoulder safety belts at the four outboard seat positions, manual lap belt at the back center position, and with frontal air bags for the two front seat positions. Its odometer reading is unknown. Its specification wheelbase was 271 centimeters [106.5 inches]. The case vehicle was towed but not due to damage.

The case vehicle sustained minor direct contact damage on the left corner area of the front bumper, with slight denting and scraping on the hood above the bumper (**Figures 1 and 2**). The bumper cover was loosened and hanging down but was not torn off completely. The left turn signal lens was broken out but the left headlamp was intact. There was an area of focal cracking on the right side of the windshield, directly above the front right passenger's air bag module (**Figures 3 and 4**), and no other glazing damage. None of the tires were deflated or restricted. There are no available photographs that show the case vehicle's interior, but this was a very minor crash and there were no intrusions.




Figure 1: Case vehicle's front, straight on (case photo #01)



Figure 2: Case vehicle's front left corner, angle view from left (case photo #02)

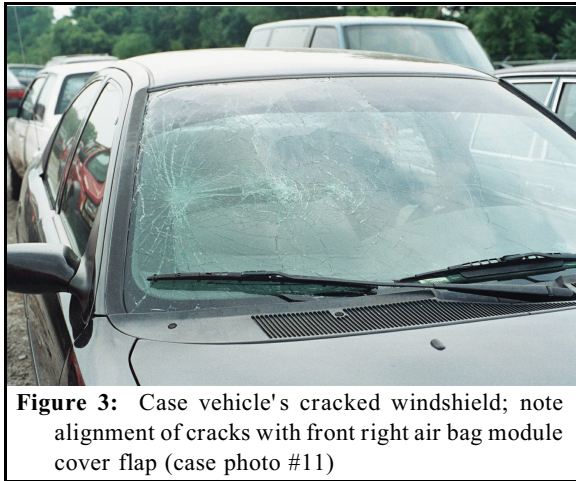

Figure 3: Case vehicle's cracked windshield; note alignment of cracks with front right air bag module cover flap (case photo #11)

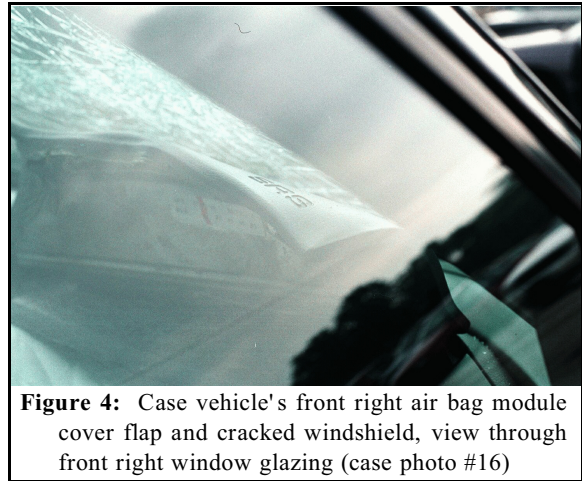

Figure 4: Case vehicle's front right air bag module cover flap and cracked windshield, view through front right window glazing (case photo #16)

The CDC for the case vehicle's single impact was estimated from the available photographs as **12-FLEE-1 (10)**. The WinSMASH reconstruction program, CDC only algorithm based on the photo estimated CDCs for the two vehicles, was used. The total, longitudinal and lateral delta-Vs for the case vehicle are, respectively: 12 km.p.h. [7.5 m.p.h.], -11.8 km.p.h. [-7.3 m.p.h.] and -2.1 km.p.h. [-1.3 m.p.h.]. This is a borderline reconstruction but the results appear reasonable. This was a crash of minor severity (1-13 km.p.h. [1-8 m.p.h.]) for the case vehicle.

The case vehicle was equipped with driver and front right passenger air bags, both of which deployed as a result of the collision events. The available photographs of the air bags were taken from outside the vehicle, through the closed windows, and are of poor quality. Accordingly, any assessments of air bag performance are limited.

The driver's air bag was mounted in the steering wheel hub (**Figure 5**). There is no knowledge of the cover flap configuration or the size of the air bag, and it is not possible to evaluate whether there was any occupant contact or damage to the driver's air bag. The one available photograph does not show any obvious evidence of contact or damage.




Figure 5: Case vehicle's driver air bag and steering wheel, view through front left window glazing (case photo #13)



Figure 6: Case vehicle's front right passenger air bag, view through front right window glazing (case photo #14)

The front right passenger's air bag was located at the right portion of the instrument panel, in the top-mount position (**Figure 6**). The areas of deformation on the air bag module cover flap align with areas of focal cracking of the windshield and it seems apparent that the cover flap impacted the windshield (see **Figure 4**). The available photographs do not show any obvious evidence of occupant contact or damage to the air bag.

CASE VEHICLE'S FRONT RIGHT OCCUPANT KINEMATICS

The front right passenger (three-month-old male, white, unknown if Hispanic, 66 centimeters, 6.8 kilograms [26 inches, 15 pounds]) was positioned facing rearward in a rear-facing child safety seat. The driver indicated that the child safety seat was secured by the vehicle's safety belt system but it is not known if the child was restrained by the child seat's harness. There is no knowledge of the front right seat's track adjustment. There is no knowledge of the make and model of the child safety seat.

The case vehicle driver did not attempt any avoidance maneuvers and the front right passenger's posture did not change. The case vehicle's front impacted the left side of the other vehicle, causing the case vehicle's driver and front right passenger air bags to deploy. The child seat and the child probably moved slightly forward and upward in response to the 12:00 o'clock direction of force. The deploying air bag struck the leading edge of the child seat, forcing it

upward and rearward. The child was positioned facing rearward, such that his head was resting on the child seat in the area where the air bag struck the child seat. The force of the deploying air bag was transmitted to the child's head, causing: a skull vault fracture across the vertex and radiating outward to the left and right parietal bones, the frontal bone, and the anterior cranial fossa; subdural hemorrhage; a small laceration of the brain in the left temporal area; subarachnoid hemorrhage over both cerebral hemispheres; massive cerebral edema; and a large subscalpular hematoma on the right. The air bag probably billowed over the child seat, contacting the child's face and causing abrasions on the right forehead, the left lateral forehead and left cheek, and a contusion on the left face within the abraded area. The child's position at final rest is not known, but the child seat probably fell back into the seat cushion with the child.

CASE VEHICLE FRONT RIGHT PASSENGER'S INJURIES

The child was transported via ground ambulance to a hospital where he was admitted. He was pronounced dead approximately 50 hours post crash.

Injury Number	Injury Description (including Aspect)	NASS Injury Code & AIS 90	Injury Source (Mechanism)	Source Confidence	Source of Injury Data
1	Nonanatomic brain injury; lethargic with prior unconsciousness; GCS = 8-9, 6, 8; with seizure and visual field defect	serious 160608.3,0	Child safety seat's back top surface {air bag-related}	Probable	Hospitalization records
2	Edema, massive, cerebral, not further specified; brain extremely soft, friable ¹ , with complications of diabetes insipidus ² ; ARDS (i.e., acute respiratory distress syndrome); and eventually pupils fixed and dilated, no response to painful stimulation, and negative brain flow examination	critical 140666.5,9	Child safety seat's back top surface {air bag-related}	Probable	Autopsy

¹ The following term is defined in DORLAND' S ILLUSTRATED MEDICAL DICTIONARY as follows:
friable (fri'a-bal): easily pulverized or crumbled.

² The following terms are defined in DORLAND' S ILLUSTRATED MEDICAL DICTIONARY as follows:
diabetes (di'e-be'tez): a general term referring to disorders characterized by excessive urine excretion (polyuria), as in diabetes mellitus and diabetes insipidus. When used alone, the term refers to diabetes mellitus.
d. insipidus, central: a metabolic disorder due to injury of the neurohypophyseal system, which results in a deficient quantity of antidiuretic hormone being released or produced, and thus in failure of tubular reabsorption of water in the kidney. As a result, a large amount of urine of low specific gravity is excreted, followed by voracious appetite, loss of strength, and emaciation. It may be inherited, acquired, or idiopathic.
fulminant (ful'm-nnt): sudden, severe; occurring suddenly and with great intensity.
syndrome (sin'drm): a set of symptoms that occur together; the sum of signs of any morbid state; a symptom complex. In genetics, a pattern of multiple malformations thought to be pathogenetically related.
acute respiratory distress syndrome: fulminant pulmonary interstitial and alveolar edema, which usually develops within a few days after the initiating trauma, thought to result from alveolar injury that has led to increased capillary permeability. Called also **adult respiratory distress s.** and **shock lung**.

Injury Number	Injury Description (including Aspect)	NASS Injury Code & AIS 90	Injury Source (Mechanism)	Source Confidence	Source of Injury Data
3	Hemorrhage, subdural, mild, not further specified as to aspect	severe 140652.4,9	Child safety seat's back top surface {air bag-related}	Probable	Autopsy
4	Laceration, small, 0.5 cm (0.2 in), left temporal area	severe 140688.4,2	Child safety seat's back top surface {air bag-related}	Probable	Hospitalization records
5 6	Hemorrhage, subarachnoid, diffuse over bilateral cerebral hemispheres (convexities) of undersurface of brain	serious 140684.3,1 140684.3,2	Child safety seat's back top surface {air bag-related}	Probable	Autopsy
7	Fracture ³ frontal bone with some comminution, not further specified	serious 150404.3,5	Child safety seat's back top surface {air bag-related}	Probable	Autopsy
8	Fracture ³ anterior cranial fossa, not further specified	serious 150200.3,8	Child safety seat's back top surface {air bag-related}	Probable	Autopsy
9 10	Fracture ³ , skull, bilaterally, across vertex ³ into both parietal bones	moderate 150402.2,1 150402.2,2	Child safety seat's back top surface {air bag-related}	Probable	Hospitalization records
11	Contusion {hematoma, hemorrhage}, large, extensive, right scalp (subscalpular)	minor 190402.1,1	Child safety seat's back top surface {air bag-related}	Probable	Autopsy
12	Abrasions x 3, superficial, right forehead area	minor 290202.1,7	Air bag, front right passenger's ⁴	Probable	Autopsy
13	Abrasion, 5.1 x 1.3 cm (2.0 x 0.5 in)] extending from left lateral forehead to left cheek	minor 290202.1,2	Air bag, front right passenger's ⁴	Probable	Autopsy
14	Contusion within left facial abrasion	minor 290402.1,2	Air bag, front right passenger's ⁴	Probable	Autopsy

NOTE: The driver indicated that this infant was in the front seat row because she believed the left rear safety belt system did not work correctly. She explained that it was not possible to correctly install the two child safety seats in the back row with a “broken” safety belt. The driver explained that the left rear safety belt was spooled out onto the seat and would not retract and,

³ In this contractor's opinion, the skull fracture on the child's vertex most likely radiated into both parietal bones (i.e., hospital records) and into the frontal bone and on into the anterior cranial fossa (i.e., autopsy). It is unknown why the different records described different fractures.

⁴ This contractor believes the air bag's fabric enveloped that portion of the seat where the child's head was and contacted the child in the forehead and face.

thus, it was not possible to correctly install a child safety seat. This contractor speculates that the “broken” safety belt may have been a switchable retractor in automatic locking mode and the driver did not know how to adjust the automatic locking mechanism.

CASE VEHICLE DRIVER'S KINEMATICS

The case vehicle driver (36-year-old female; race/ethnicity, height and weight unknown) was restrained by the available, manual, three-point, lap-and-shoulder safety belt system. Her pre-crash seat adjustments are not known, but she was probably in a normal driving posture, with at least one hand on the steering wheel and her feet on the floor or operating the foot controls.

The driver did not attempt any avoidance maneuvers and her posture did not change immediately prior to the crash. The case vehicle's front impacted the left front area of the other vehicle, causing the case vehicle's driver and front right passenger air bags to deploy. The driver moved slightly forward and upward in response to the 12:00 o'clock direction of force, but was held in place by her safety belt. She probably encountered the air bag with her face and chest and she stated to the police that she sustained bruises from the air bag. She also reported a contusion across her lower abdomen from the safety belt. At final rest, she probably remained in an upright posture in the driver's seat.

DRIVER'S INJURIES

The driver accompanied the front right passenger in the ambulance to the hospital, but there was no record at the hospital that she was treated.

CASE VEHICLE DRIVER INJURIES

Injury Number	Injury Description (including Aspect)	NASS Injury Code & AIS 90	Injury Source (Mechanism)	Source Confidence	Source of Injury Data
1.	“ Seat belt bruises across lower abdomen”	minor 590402.1,8	Driver's safety belt webbing	Probable	Police Report
2.	“ Bruises from air bag” NFS	minor 990400.1,9	Driver's air bag	Probable	Police Report

CASE VEHICLE BACK LEFT PASSENGER'S KINEMATICS

The case vehicle's back left passenger (34-year-old female; race/ethnicity, height and weight unknown) was not using the available, active, three-point, lap-and-shoulder safety belt system. The driver's discussion of the perceived problem with the back left safety belt system was presented above (see note following Front Right Passenger's Injuries). The back left passenger was leaning to her right, buckling the back right passenger's shoe. She stated to the police that her left shoulder was against the driver's seat back as she leaned over to attend to the back left passenger.

The driver did not attempt any avoidance maneuvers and the back left passenger's posture did not change immediately prior to the crash. The case vehicle's front impacted the left front area of the other vehicle and the back left passenger moved slightly forward and upward in response to the 12:00 o'clock direction of force. Her left shoulder probably loaded against the driver's seat back. She stated to the police that she had pain in her neck and shoulder but did not describe any specific injury.

The back left passenger accompanied the driver and the front right passenger in the ambulance, but there was no record that she was treated. In her statement to the police, the back left passenger complained of pain in her neck and shoulder but did not describe any specific injury.

CASE VEHICLE BACK RIGHT PASSENGER'S KINEMATICS

The case vehicle's back right passenger (3-year-old male, race/ethnicity, height and weight unknown) was seated in a high-back booster seat with padded upholstery and a five-point harness. There is no knowledge concerning the make and model of the booster seat. According to the driver's statement, the booster seat was secured by the available, active, three-point, lap-and-shoulder safety belt system and the child was restrained by the booster seat's harness. There is no evidence to refute or support this assertion, except to note that this child did not sustain any injuries. He was probably seated in the child seat with his back against the child seat's back and his feet dangling over the front of the vehicle's seat cushion. The back left adult passenger was buckling this child's shoe.

The driver did not attempt any avoidance maneuvers and the back right passenger's posture did not change immediately prior to the crash. The case vehicle's front impacted the left front area of the other vehicle and the back right passenger probably moved slightly forward and upward in response to the 12:00 o'clock direction of force, but was held in place by the booster seat's harness. At final rest, he probably remained in an upright posture in the booster seat.

The back right passenger accompanied the other occupants in the ambulance, but there was no record that he was treated. In her statement to the police, the driver (this child's mother) stated that he did not sustain any injuries.




Figure 7: High back booster seat in back right seat position, view through left rear window glazing (case photo #18a)

OTHER VEHICLE

The other vehicle was a 1996 Buick Regal front wheel drive, four-door, six passenger sedan (VIN: 2G4WB52K2T1-----), equipped with a 3.8 liter V6 gasoline engine. The Buick was fitted with dual frontal air bags that did not deploy. Its odometer reading is not known and its wheelbase

was 273 centimeters [107.5 inches]. The Buick was driven away from the scene.

The Buick sustained denting and scraping in the area of the left front overhang. The fender and the left corner of the front bumper were crushed inward but the left headlamp/turn signal assembly was intact. There was no glazing damage and none of the tires were deflated or restricted.

The CDC for the Buick's single impact was estimated from the available photographs as **10-LFEW-2 (310)**. The WinSMASH reconstruction program, CDC only algorithm based on the photo estimated CDCs for the two vehicles, was used. The total, longitudinal and lateral delta-Vs for the Buick are, respectively: 10 km.p.h. [6.2 m.p.h.], -6.4 km.p.h. [-4.0 m.p.h.] and + 7.7 km.p.h. [+ 4.8 m.p.h.]. This is a borderline reconstruction but the results appear reasonable. This was a crash of minor severity (1-13 km.p.h. [1-8 m.p.h.]) for the Buick.


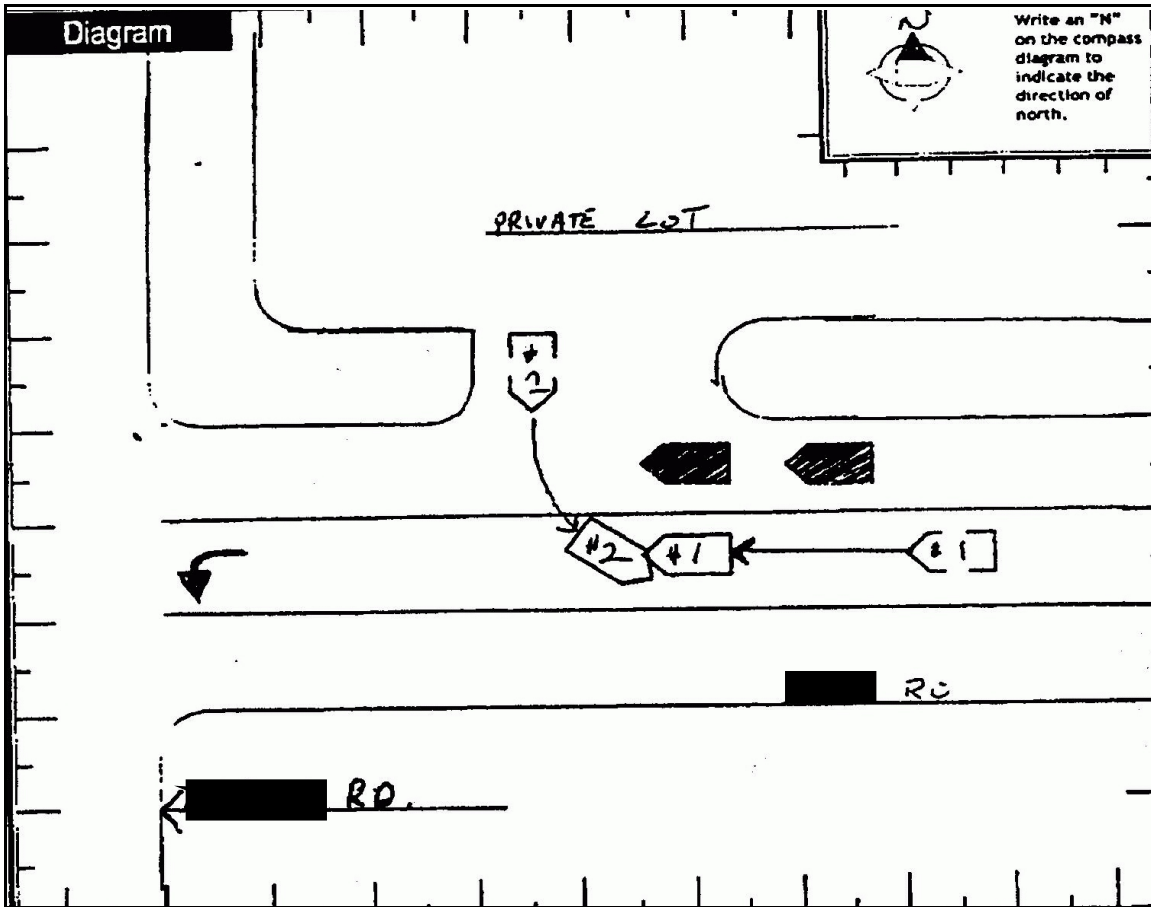


Figure 8: Buick's left front corner (case photo #20)

According to the police crash report, the Buick's driver (54-year-old female, race/ethnicity, height and weight unknown) was restrained by her available, active, three-point, lap-and-shoulder safety belt system. The driver was not transported by ambulance to a hospital, and, according to the police report, she did not sustain any injuries as a result of this crash.



Copied from police crash report.