



INDIANA UNIVERSITY

TRANSPORTATION RESEARCH CENTER

School of Public and Environmental Affairs
222 West Second Street
Bloomington, Indiana 47403-1501
(812) 855-3908 Fax: (812) 855-3537

REMOTE AIR BAG FATALITY REPORT

CASE NUMBER - IN-03-019

LOCATION - Alaska

VEHICLE - 1995 MERCURY MYSTIQUE LS

CRASH DATE - March 2001

Submitted:

December 9, 2003

Revised:

October 5, 2004



Contract Number: DTNH22-01-C-07022

Prepared for:

U.S. Department of Transportation
National Highway Traffic Safety Administration
National Center for Statistics and Analysis
Washington, D.C. 20590-0003

DISCLAIMERS

This document is disseminated under the sponsorship of the Department of Transportation in the interest of information exchange. The United States Government assumes no responsibility for the contents or use thereof.

The opinions, findings, and conclusions expressed in this publication are those of the authors and not necessarily those of the National Highway Traffic Safety Administration.

The crash investigation process is an inexact science which requires that physical evidence such as skid marks, vehicular damage measurements, and occupant contact points be coupled with the investigator's expert knowledge and experience of vehicle dynamics and occupant kinematics in order to determine the pre-crash, crash, and post-crash movements of involved vehicles and occupants.

Because each crash is a unique sequence of events, generalized conclusions cannot be made concerning the crashworthiness performance of the involved vehicle(s) or their safety systems.

1. Report No. IN-03-019		2. Government Accession No.		3. Recipient's Catalog No.	
4. Title and Subtitle On-Site Air Bag Fatality Investigation Vehicle - 1995 Mercury Mystique LS Location - Alaska			5. Report Date: December 9, 2003		
			6. Performing Organization Code		
7. Author(s) Special Crash Investigations Team #2			8. Performing Organization Report No.		
9. Performing Organization Name and Address Transportation Research Center Indiana University 222 West Second Street Bloomington, Indiana 47403-1501			10. Work Unit No. (TRAIS)		
			11. Contract or Grant No. DTNH22-01-C-07002		
12. Sponsoring Agency Name and Address U.S. Department of Transportation (NRD-32) National Highway Traffic Safety Administration National Center for Statistics and Analysis Washington, D.C. 20590-0003			13. Type of Report and Period Covered Technical Report Crash Date: March 2001		
			14. Sponsoring Agency Code		
15. Supplementary Notes Remote investigation involving a 1995 Mercury Mystique equipped with manual safety belts and dual frontal air bags that impacted a dead moose that was lying in the road.					
16. Abstract This report covers a remote investigation of an air bag deployment crash involving 1995 Mercury Mystique that impacted a dead moose that was lying in the road. This crash is of special interest because the case vehicle's unrestrained front right passenger (5-year-old male) sustained a fatal cervical spinal cord injury as a result of being struck by the deploying front right passenger's air bag module cover flap. The case vehicle was traveling east in the eastbound lane of a two-lane, undivided county roadway and intended to continue in its eastward path of travel. The moose was lying, dead (or very seriously injured), in the eastbound lane of the same roadway. It was dark with no street lights, the asphalt road surface was dry and free of defects, and the weather clear and very cold (-22 degrees Fahrenheit). The case vehicle's driver saw the dead moose and braked in an attempt to avoid the crash, depositing 13.7 meters [45 feet] (police measured) of lock-up braking skid marks prior to the impact. The lower front and undercarriage of the case vehicle impacted the moose, causing the case vehicle's driver and front right passenger air bags to deploy. The case vehicle ran over the moose and was brought to a controlled stop on the right shoulder. The unrestrained front right passenger moved forward in response to the pre-impact braking deceleration and was in very close proximity to the front right air bag module when the air bag deployed. His injuries included atlanto-occipital dislocation with complete transection of the spinal cord, subarachnoid hemorrhage over the base of the brain, fracture of the right mandible, a gaping laceration under his chin on the right, and various contusions and abrasions. He was declared dead at the scene. The restrained case vehicle driver (15-year-old male) sustained minor soft tissue injuries and was treated and released at a local health clinic. The case vehicle was towed due to disabling engine damage.					
17. Key Words Air Bag Deployment			Motor Vehicle Traffic Crash Injury Severity		
18. Distribution Statement General Public					
19. Security Classif. (of this report) Unclassified		20. Security Classif. (of this page) Unclassified		21. No. of Pages 6	22. Price \$3,200

TABLE OF CONTENTS

IN-03-019

	<u>Page No.</u>
BACKGROUND	1
CRASH CIRCUMSTANCES	1
CASE VEHICLE: 1995 MERCURY MYSTIQUE LS	2
CASE VEHICLE FRONT RIGHT PASSENGER	3
PASSENGER'S INJURIES	4
CASE VEHICLE DRIVER	5
DRIVER'S INJURIES	5
POLICE SCENE SCHEMATIC	6
 SELECTED PHOTOGRAPHS	
Figure 1: Looking west toward the case vehicle's eastbound approach	1
Figure 2: The dead moose	1
Figure 3: Front of case vehicle	2
Figure 4: Left side of case vehicle	2
Figure 5: Right side of case vehicle	2
Figure 6: Driver and front right passenger air bags deployed	3
Figure 7: Front right air bag module cover flap and right windshield	3
Figure 8: Closeup, front right air bag module cover flap	3

This remote air bag fatality report was brought to the NHTSA's attention in June 2003 by a review of the 2001 Fatality Analysis Reporting System (FARS) file. This crash involved a 1995 Mercury Mystique LS (case vehicle) and a non-fixed object (i.e., a dead moose lying in the roadway). The crash occurred in March 2001, at 11:54 p.m., in Alaska and was investigated by the applicable state police. This crash is of special interest because the case vehicle's front right passenger (5-year-old male, white, non-Hispanic) sustained a fatal cervical spinal cord injury as a result of being struck by the deploying front right passenger air bag module cover flap. This contractor received the police investigative materials on July 2, 2003 and received the fatal victim's autopsy report on October 20, 2003. This report is based on the police crash report, police photographs, the autopsy report and this contractor's evaluation of the evidence.

CRASH CIRCUMSTANCES

The case vehicle was traveling east in the eastbound lane of a two-lane, undivided county roadway and intended to continue in its eastward path of travel (**Figure 1**). The moose was lying, dead (or very seriously injured), in the eastbound lane of the same roadway. The moose had been injured as a result of a previous crash with a pickup truck approximately 15 - 20 minutes prior. (The moose apparently ran away from the first crash and could not be found, but wandered back onto the roadway where it collapsed.) It was dark with no street lights, the asphalt road surface was dry and free of defects, and the speed limit was 86 km.p.h. [55 m.p.h.]. The weather clear and very cold (-22 degrees Fahrenheit). The case vehicle's driver saw the dead moose and braked in an attempt to avoid the crash, depositing 13.7 meters [45 feet] (police measured) of lock-up braking skid marks prior to the impact. The crash occurred in the eastbound lane of the roadway.

The lower front and undercarriage of the case vehicle impacted the moose (**Figure 2**), causing the case vehicle's driver and front right passenger air bags to deploy. The police estimated that the case vehicle had been traveling approximately 80 km.p.h. [50 m.p.h.] prior to the crash and had slowed to approximately 64 km.p.h. [40 m.p.h.] when it hit the moose. The case vehicle ran over the moose (the police report indicates "jumped over") and was brought to a controlled stop approximately 45.7 meters [150 feet] beyond the point of impact, on the right (south) shoulder.



Figure 1: Looking west toward the case vehicle's eastward travel path, with post-impact skid marks visible in the foreground (case photo #01)

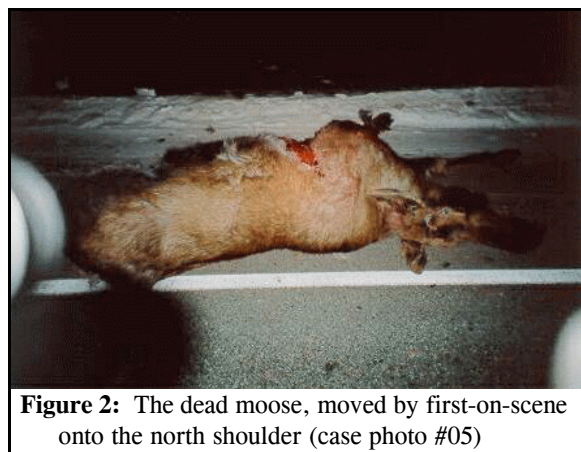


Figure 2: The dead moose, moved by first-on-scene onto the north shoulder (case photo #05)

The case vehicle was a 1995 Mercury Mystique LS front wheel drive, four-door, five-passenger sedan (VIN: 1MELM66L9SK-----), equipped with a 2.5 liter V6 gasoline engine and a manual transmission with a floor/console-mounted shift lever. Anti-lock brakes were an option for this model vehicle, but the case vehicle was apparently not equipped (as evidenced by the presence of lock-up braking skid marks). The case vehicle's wheelbase was 271 centimeters [106.7 inches] and the police reported its odometer reading as 43,311 kilometers [26,912 miles]. The case vehicle was towed due to damage.

The case vehicle's front bumper and undercarriage impacted and ran over the moose (**Figure 3**). Portions of the front bumper cover were broken away and moose fur was lodged in the lower edge of the steel bumper and radiator support. The radiator and engine oil pan were damaged, causing substantial leakage of coolant and oil at the scene. There was a star-shaped crack in the windshield on the right and no other glazing damage. The left front wheel was visibly displaced rearward, but there was no other obvious damage to the wheels or tires. A large smear of the moose's blood was splashed onto the left rear wheel and body panels (**Figure 4**). The case vehicle's right side did not sustain any obvious damage (**Figure 5**), except the front right bumper cover was broken away. The CDC was estimated from photographs as **12-FDLW-1 (0)**. This crash is out of scope for the WinSMASH reconstruction program (yielding object). This was a crash of low severity (11-23 km.p.h. [9 - 14 m.p.h.]) for the case vehicle.

The police photographs show that the driver's air bag was mounted in the steering wheel hub, the front right passenger's air bag was located in the top of the instrument panel and both air bags deployed (**Figure 6**). There was no obvious damage to the driver's air bag or cover flaps, and there was no contact evidence on the driver's air bag fabric visible in the photographs.



Figure 3: Front of case vehicle at tow yard; note tufts of moose fur (case photo #13)



Figure 4: Left side of case vehicle on-scene; note, left bumper cover broken away, left front wheel displaced rearward, blood from moose on left rear quarter panel (case photo #09)



Figure 5: Right side of case vehicle at tow yard; note front right corner of bumper cover broken away (case photo #21)

The front right passenger's air bag cover flap was visibly deformed, with a V-shaped bend at the front-center of the cover flap (**Figures 7 and 8**). There was a small amount of blood smeared on the air bag's fabric, with no other evidence of contact and no obvious damage to the air bag.

CASE VEHICLE FRONT RIGHT PASSENGER

The front right passenger (5-year-old male, white, non-Hispanic, 109 centimeters, 17 kilograms [43 inches, 38 pounds]) was not restrained by the available, active, three-point, lap-and-shoulder safety belt system. His pre-crash posture and seat adjustments are not known.

The case vehicle driver braked in an attempt to avoid hitting the moose and the front right passenger moved forward in response to the braking deceleration, putting the child in very close proximity to the front right air bag module. The front of the case vehicle impacted the moose, causing the case vehicle's air bags to deploy. The deploying front right air bag cover flap struck him under the chin, moving his head upward and rearward and causing atlanto-occipital dislocation and transection of the spinal cord. The cover flap also caused a fracture of his right mandible with dislocation of several teeth, and created a gaping laceration and contusions on the under side of his chin, mostly on the right. In combination with the relatively minor impact deceleration, the deploying air bag lifted the child upward and his forehead impacted the windshield, creating a focal crack in the windshield and causing contusions and abrasions on his forehead. The air bag impacted his torso, causing abrasions in the area of his right clavicle. His lower legs impacted the knee bolster, causing multiple contusions on his knees and lower legs, bilaterally. He fell back into the seat and sustained a contusion on his upper right thigh. The driver reported that when the case vehicle came to rest, the front right passenger was on the floor in the front right area.



Figure 6: Case vehicle's front seat, showing deployed air bags (case photo #24)

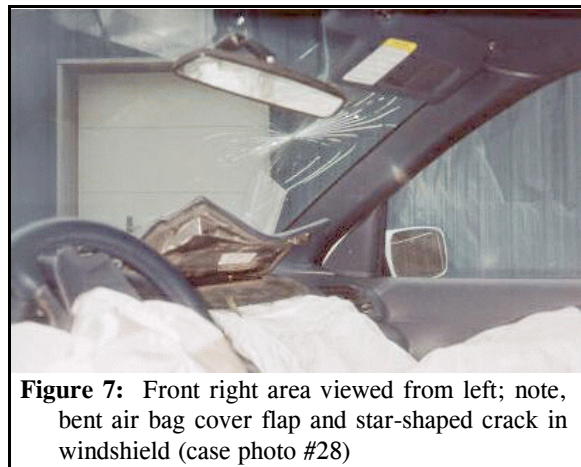


Figure 7: Front right area viewed from left; note, bent air bag cover flap and star-shaped crack in windshield (case photo #28)




Figure 8: Close-up, front right passenger's air bag cover flap (case photo #27)

CASE VEHICLE FRONT RIGHT PASSENGER INJURIES

IN-03-019

The front right passenger was declared dead at the scene and did not receive any medical treatment.

Injury Number	Injury Description (including Aspect)	NASS Injury Code & AIS 90	Injury Source (Mechanism)	Source Confidence	Source of Injury Data
1	Transection of spinal cord just below foramen magnum with posterior displacement of cord and atlanto-occipital dislocation	maximum 640274.6 ¹ ,6	Front right module's cover flap	Certain	Autopsy
2 3	Hemorrhage, subarachnoid, extending inferiorly over base of brain and over left and right cerebral hemispheres	serious 140684.3,1 140684.3,2	Front right module's cover flap	Probable	Autopsy
4	Fracture right mandible with displacement, not further specified as to location	moderate 250610.2,1	Front right module's cover flap	Certain	Autopsy
5	Dislocation of lower teeth, not further specified, secondary to mandibular fracture	minor 251402.1,8	Front right module's cover flap	Certain	Autopsy
6	Avulsion {missing/lost} lower incisor teeth, not further specified	minor 251406.1,8	Front right module's cover flap	Certain	Autopsy
7	Abrasions, 7.6 x 5.1 cm (3 x 2 in) area over upper medial forehead	minor 290202.1,7	Front right windshield's glazing	Probable	Autopsy
8	Contusion {bruise}, 2.5 cm (1 in) maximum, left forehead	minor 290402.1,7	Front right windshield's glazing	Probable	Autopsy
9	Laceration 1.9 x 1.3 cm (0.75 x 0.5 in) lower frenulum	minor 290602.1,8	Front right module's cover flap	Possible	Autopsy
10	Laceration, 8.9 x 2.5 cm (3.5 x 1 in), gaping, under chin from midline toward right cheek	minor 290602.1,8	Front right module's cover flap	Certain	Autopsy
11	Contusions {discolorations}, 22.9 x 7.6 cm (9 x 3 in) underneath chin from left cheek to off right side of face	minor 290402.1,8	Front right module's cover flap	Probable	Autopsy
12	Abrasion over right medial clavicle	minor 790202.1,1	Air bag, front right passenger's	Probable	Autopsy

¹ The choice of injury code is difficult because the NASS CDS Injury Coding manual presumes that one knows whether there was a complete or an incomplete cord syndrome. Because the only available medical record is an autopsy, the syndrome issue is not discernable (i.e., you cannot determine the difference in a deceased person). In the absence of protocol, this contractor chooses to assume that the syndrome was complete.

Injury Number	Injury Description (including Aspect)	NASS Injury Code & AIS 90	Injury Source (Mechanism)	Source Confidence	Source of Injury Data
13	Contusion {bruise}, 3.8 cm (1.5 in) over right lateral upper thigh	minor 890402.1,1	Seat cushion, front right passenger's	Possible	Autopsy
14	Contusions, multiple, irregular, over both knees and lower legs	minor 890402.1,3	Knee bolster, front right passenger's	Probable	Autopsy

CASE VEHICLE DRIVER

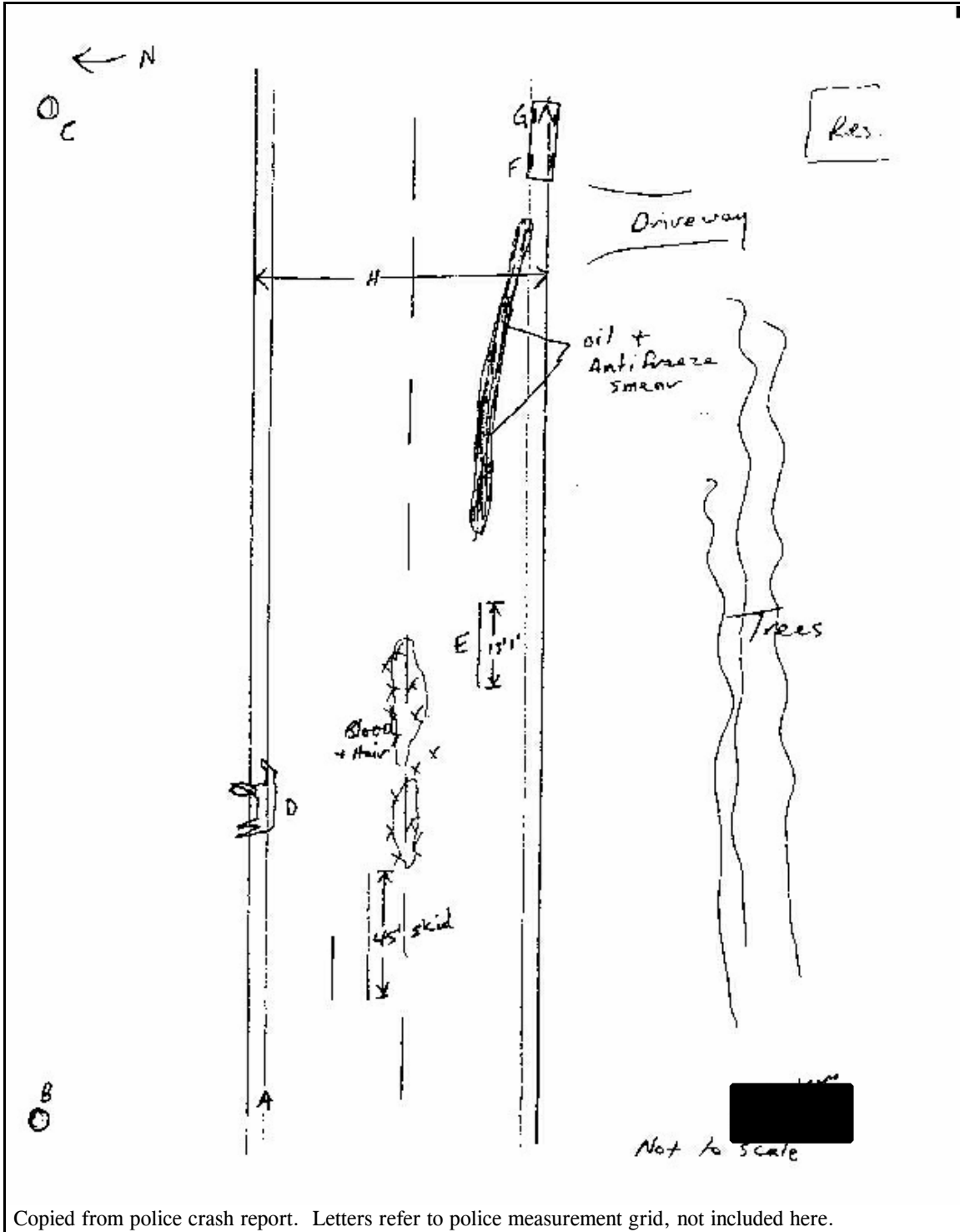
The case vehicle driver (15-year-old male, white, non-Hispanic, 165 centimeters, 54 kilograms [65 inches, 120 pounds]) was restrained by his available, active, three-point, lap-and-shoulder safety belt system. His pre-crash posture and seat adjustments are not known, but he certainly had one foot on the brake pedal and at least one hand on the steering wheel.

The driver saw the dead moose in the road and braked, attempting to avoid the impact. He probably moved slightly forward in response to the braking deceleration, but the safety belt system and the force of his leg pressure on the brake pedal held him essentially in place. The front of the case vehicle impacted the moose, causing the case vehicle's air bags to deploy. The driver's air bag probably deployed against his chest, perhaps contacting his forearms as he gripped the steering wheel, and then deflated as he moved slightly forward in response to the relatively minor impact deceleration. The driver continued braking and steered the case vehicle onto the right shoulder, where he brought it to a controlled stop.

DRIVER'S INJURIES

The driver was transported via ambulance to a local health clinic, where he was treated and released. His medical records were not acquired. He sustained police-reported "C" (possible) injuries, self-reported as a "bump on the wrist".

Injury Number	Injury Description (including Aspect)	NASS Injury Code & AIS 90	Injury Source (Mechanism)	Source Confidence	Source of Injury Data
1	Contusion ("bump"), wrist, aspect unknown	790402.1 minor	Driver's air bag	possible	Police Report



Copied from police crash report. Letters refer to police measurement grid, not included here.