

TRANSPORTATION SCIENCES
Crash Research Section

Veridian Engineering
Calspan Operations
Buffalo, New York

**CALSPAN ON-SITE AIR BAG DEPLOYMENT/ADULT PASSENGER
SEVERE INJURY INVESTIGATION
CALSPAN CASE NO. CA97-043
VEHICLE: 1995 GEO METRO
LOCATION: PENNSYLVANIA
CRASH DATE: JULY 1997**

Contract No.
DTNH22-94-D-07058

Prepared For:

U.S. Department of Transportation
National Highway Traffic Safety Administration
Washington, D.C. 20590

DISCLAIMER

This document is disseminated under the sponsorship of the Department of Transportation in the interest of information exchange. The United States Government assumes no responsibility for the contents or use thereof.

The opinions, findings, and conclusions expressed in this publication are those of the authors and not necessarily those of the National Highway Traffic Safety Administration.

The crash investigation process is an inexact science which requires that physical evidence such as skid marks, vehicular damage measurements, and occupant contact points are coupled with the investigator's expert knowledge and experience of vehicle dynamics and occupant kinematics in order to determine the pre-crash, crash, and post-crash movements of involved vehicles and occupants.

Because each crash is a unique sequence of events, generalized conclusions cannot be made concerning the crashworthiness performance of the involved vehicle(s) or their safety systems.

TECHNICAL REPORT STANDARD TITLE PAGE

<p>1. <i>Report No.</i> CA97-043</p>	<p>2. <i>Government Accession No.</i></p>	<p>3. <i>Recipient's Catalog No.</i></p>	
<p>4. <i>Title and Subtitle</i> Calspan On-Site Air Bag Deployment/Adult Passenger Severe Injury Investigation Vehicle: 1995 Geo Metro Location: Pennsylvania</p>		<p>5. <i>Report Date:</i> April 2000</p>	
		<p>6. <i>Performing Organization Code</i></p>	
<p>7. <i>Author(s)</i> Crash Research Section</p>		<p>8. <i>Performing Organization Report No.</i></p>	
<p>9. <i>Performing Organization Name and Address</i> Transportation Sciences Crash Research Section Calspan Operations P.O. Box 400 Buffalo, New York 14225</p>		<p>10. <i>Work Unit No.</i> C01115.0000.(81110-8119)</p>	
		<p>11. <i>Contract or Grant No.</i> DTNH22-94-D-07058</p>	
<p>12. <i>Sponsoring Agency Name and Address</i> U.S. Department of Transportation National Highway Traffic Safety Administration Washington, D.C. 20590</p>		<p>13. <i>Type of Report and Period Covered</i> Technical Report Crash Date: July 1997</p>	
		<p>14. <i>Sponsoring Agency Code</i></p>	
<p>15. <i>Supplementary Notes</i> On-site investigation of a run-off-road crash that resulted in air bag deployment and a cervical injury to the 55 year old female front right passenger.</p>			
<p>16. <i>Abstract</i> This on-site investigation focused on a single vehicle run-off-road crash that involved a 1995 Geo Metro that was equipped with frontal air bags for the driver and passenger positions. The front center and right areas of the Metro impacted a rock embankment which resulted in deployment of the air bag systems. The driver was restrained by the manual belt system. He sustained a nasal abrasion from contact with the front left air bag. The 55 year old female front right passenger was seated in a forward track position. The expanding front right air bag contacted her arms which resulted in abrasions and contusions. Her arms were displaced rearward, and in combination with bag expansion, her neck was hyper-extended resulting in a fracture dislocation of C6/C7 with quadriplegia. She also sustained multiple bilateral rib fractures from the air bag expansion. The passenger was transported to a local hospital where she was evaluated and prepared for air transferal to a major medical center where she was admitted for treatment. The passenger expired 149 days post-crash due to respiratory complications.</p>			
<p>17. <i>Key Words</i> Frontal driver air bag deployment Adult front right passenger Critical injuries</p>		<p>18. <i>Distribution Statement</i> General Public</p>	
<p>19. <i>Security Classif. (of this report)</i> Unclassified</p>	<p>20. <i>Security Classif. (of this page)</i> Unclassified</p>	<p>21. <i>No. of Pages</i> 12</p>	<p>22. <i>Price</i></p>

TABLE OF CONTENTS

BACKGROUND	1
SUMMARY	
Crash Site	2
Vehicle Data	2
Crash Sequence	
Pre-Crash	2
Crash	3
Post-Crash	3
VEHICLE DAMAGE	
Exterior	3
Interior	4
MANUAL RESTRAINT SYSTEMS	5
AUTOMATIC RESTRAINT SYSTEM	6
DRIVER DEMOGRAPHICS	8
DRIVER INJURIES	8
DRIVER KINEMATICS	8
FRONT RIGHT PASSENGER DEMOGRAPHICS	9
FRONT RIGHT PASSENGER INJURIES	9
FRONT RIGHT PASSENGER KINEMATICS	10
MEDICAL TREATMENT	11

**CALSPAN ON-SITE AIR BAG DEPLOYMENT/ADULT PASSENGER
SEVERE INJURY INVESTIGATION
CALSPAN CASE NO. CA 97-043
VEHICLE:1995 GEO METRO
LOCATION: STATE OF PENNSYLVANIA
CRASH DATE: JULY 1997**

BACKGROUND

This investigation focused on a single vehicle run-off-road crash that involved a 1995 Geo Metro, 2-door hatchback. The Metro was equipped with frontal air bags for the driver and front right passenger positions that deployed as a result of a frontal impact with a rock embankment (**Figure 1**). The driver of the vehicle had stopped at a T-intersection which was controlled by a stop sign. He initiated a left turn onto a northbound 2-lane asphalt roadway and traveled approximately 400 meters (1,312 feet) when several dogs allegedly ran into the road. The driver took evasive action by steering right and braking to avoid the animals. The vehicle subsequently departed the right side of the road where the front center and right areas of the bumper, hood, and right front fender impacted an overhanging rock embankment. The 12 o'clock direction of force impact deployed the frontal air bags.



Figure 1. Front right view of the vehicle damage.

The 69 year old male driver of the Geo was restrained by the manual belt system. He sustained nasal abrasions with epistaxis (nose bleed) from his contact with the deployed front left air bag. The 55 year old female front right passenger was seated in a forward position and was restrained by the manual belt system. She raised her arms in an attempt to brace prior to impact with the embankment. The expanding front right air bag contused and abraded her arms and expanded against her face and/or neck which resulted in C6/C7 fracture dislocation with complete quadriplegia. The air bag membrane also contacted the passenger chest which resulted in multiple bilateral rib fractures with pulmonary edema. The passenger was initially transported to a local hospital where her cervical injury was diagnosed. She was transferred to a major medical center where she was admitted for 40 days then discharged to a rehabilitation facility where she received seven days of treatment. Respiratory complications developed as a result of the cervical injury and she was returned to the hospital. The passenger expired 149 days post-crash due to respiratory complications.

The crash occurred in July 1997. An attorney representing the family notified the Special Crash Investigation program of this serious injury crash on October 29, 1997. The investigation was subsequently assigned to Calspan's Special Crash Investigation Team on this day and an on-site investigation was initiated on October 30, 1997.

SUMMARY

Crash Site

The crash occurred at dusk on a rural two-lane asphalt state route which curved to the left with respect to the vehicle's path of travel. The weather was clear and the road surface was dry with a slight negative grade of 1 percent to the north at the impact location. An overhead luminaire lighted the roadway in the vicinity of the crash site. The travel lanes were bordered by narrow asphalt shoulders with an earth and stone embankment bordering the east edge of the roadway at the apex of the left curve (**Figure 2**). The posted speed limit was 64 km/h (40 mph).



Figure 2. Overall view of the approach to the crash site.

Vehicle Data

The 1995 Geo Metro was a 2-door hatchback, equipped with a 3-cylinder, 1.0 L transverse mounted engine linked to a 5-speed manual transmission with a floor mounted shifter. Braking was achieved by power-assisted front disc/rear drum brakes without anti-lock (ABS). The vehicle was manufactured on 06/95 and identified by vehicle identification number 2C1MR2260S6 (production number omitted). The vehicle was inspected at the driver's residence and all crash related damage remained intact. At the time of the crash, the vehicle's odometer reading was 41,261 kilometers (25,639 miles). The Metro was configured with front bucket seats with manual track adjusters and reclining/forward folding seat back supports with integral head restraints. In addition to the frontal air bag system, the Metro was equipped with 3-point manual belt systems for the four designated seated positions.

The vehicle was purchased for the owner as a gift in the early winter months of 1995. The Geo was involved in a previous crash in February 1996. The frontal air bags did not deploy as a result of this previous crash. This was verified by the body shop invoice which noted a total repair cost of \$1,044. It should be noted that the front seat belt systems were not replaced for the repair.

Crash Sequence

Pre-Crash

The driver of the vehicle was intoxicated with a police reported BAC of .184. He was returning to his residence and was traveling in an easterly direction on a 2-lane road. The driver stopped at a 3-leg T intersection which was controlled by a stop sign. He initiated a left turn onto the 2-lane asphalt roadway and traveled northbound approximately 400 meters (1,312 feet) at a driver estimated speed of 40 km/h (25 mph). As he was descending the negative grade and negotiating the left curve, the driver reported several dogs ran into the road from right to left across the vehicle's path of travel. The driver took evasive action to avoid the animals by swerving right and braking. The scene inspection, which was conducted more than three months post-crash, revealed 2.6 meters (8.5') of right front skid marks and 2.4 meters (7.8') of left front skid marks departing the right road edge. The investigating police officer documented 4 meters (13') of pre-crash skidding during his on-scene investigation of the crash. [Assuming the skid

distance of 4 m and the WinSMASH computed impact speed noted below, the Geo's initial travel speed was computed at 46.0 km/h (28.6 mph)]

Crash

The Geo Metro subsequently departed the right side of the road in a near tracking orientation and impacted an overhanging rock embankment (**Figure 3**) that was located 0.5 meters (1.6 feet) outboard of the northbound travel lane. Initial contact involved the right and center aspects of the hood and right front fender of the vehicle against the overhanging aspect of the embankment. As the Geo continued forward, the bumper engaged against the rock embankment. Due to the overhanging structure and the sheet metal engagement, the crash was borderline for computer reconstruction. The outputs of the WinSMASH program were reasonable, therefore the reconstruction was allowed for this crash. Impact speed was computed by the damage and trajectory algorithm of the WinSMASH program at 36.3 km/h (22.6 mph). The total velocity change for this 12 o'clock direction of force impact was 17.7 km/h (11.0 mph) with a longitudinal component of -17.6 (-10.9 mph). This impact induced deceleration was sufficient to deploy the vehicle's frontal air bag systems, however, due to the overhanging structure, the crash pulse was probably elongated which deployed the air bags late in the crash sequence.



Figure 3. Overhanging rock embankment.

As the structure of the Geo Metro engaged against the embankment, the vehicle began to rotate in a clockwise (CW) direction. The Geo rotated approximately 104 degrees CW and came to final rest facing in an easterly direction, perpendicular to the northbound travel lane, approximately 4 m (13') north of its at impact location. The Crash Schematic is attached as **Figure 15**, Page 12.

Post-Crash

The driver came to rest in an upright attitude in his seated position. He stated that the passenger was displaced laterally to the left and that he held her until the arrival of rescue personnel. Volunteer fire personnel were first to arrive on-scene. The emergency medical technicians (EMTs) responded to the call and stabilized the passenger in the vehicle prior to removing her on a backboard. She was transported by ambulance to a local hospital where she was diagnosed with a cervical injury. The passenger was prepared for helicopter transfer to a major medical center (non-trauma) for treatment of the injury.

VEHICLE DAMAGE

Exterior

Damage to the Geo was rated as moderate with a maximum crush value of 8.7 cm (3.4") located at the right corner of the upper radiator support panel. Direct contact damage on the hood face began 2.5 cm (1.0") right of center and extended 66.0 cm (26.0") to the front right corner (**Figure 4**). The direct damage on the bumper fascia began 53.3 cm (21.0") right of center and extended 12.7 cm (5.0") to the front right corner. Crush measurements were documented at bumper level and the level of the upper radiator support

panel and are displayed below in **Table 1** . **Figure 5** is a profile view of the crush depth. The Principle Direction of Force (PDOF) was +5 degrees and the damage yielded a Collision Deformation Classification (CDC) of 12-FZEW-1.



Figure 4. Frontal damage to the Geo Metro.



Figure 5. Profile view of the frontal crush.

**Table 1.
Crush Profiles**

Crush Measurement	C1	C2	C3	C4	C5	C6
Front bumper	0 cm (0 in)	0 cm (0 in)	0.4 cm (0.2 in)	0.9 cm (0.4 in)	1.9 cm (0.7 in)	3.2 cm (1.3 in)
Front radiator support	0 cm (0 in)	4.9 cm (1.9 in)	5.9 cm (2.3 in)	7.1 cm (2.8 in)	7.4 cm (2.9 in)	8.7 cm (3.4 in)
Resulting average crush	0.0 cm (0 in)	2.4 cm (0.9 in)	3.2 cm (1.25 in)	4.1 cm (1.6 in)	4.6 cm (1.8 in)	6.0 cm (2.4 in)

Interior

Interior damage to the Geo Metro was minor in severity and was associated with occupant contact and deployment of the frontal air bag systems. There was no interior intrusion or damage resulting from exterior deformation. Air bag deployment damage was limited to the opening of the module covers at the designated tear seams. The expansion of the front right air bag against the passenger resulted in an altered deployment path of the bag membrane which resulted in separation of the rear view mirror and membrane fabric transfers to the windshield and the right door panel.

The driver loaded the manual belt system during the crash which resulted in a superficial D-ring transfer to the shoulder belt webbing. He additionally loaded the deployed front left air bag, however, no contact evidence was noted to the bag. Several blood spatters were documented to the bag which resulted post-crash from his epistaxis.

The front right passenger was seated in a forward track position with her arms extended forward of her body at impact. The front right air bag expanded against her arms resulting in soft tissue abrasions and contusions. Tissue fragments were noted to the lower right quadrant of the bag membrane. Several vinyl

transfers were noted to the bag from expansion within the module as the passenger's position restricted the normal deployment path of the bag. A band-like transfer was noted to the lower mid aspect of the bag, wrapping onto the bottom of the membrane. Several blood spatters were also noted to the bag. These points are documented in **Figure 6**.

The front right air bag fabric transferred onto the shoulder belt webbing as the bag expanded against the passenger. The subtle transfer was located below a blood stain on the belt webbing (**Figure 7**). There was no contact evidence to the module covers or knee bolsters.



Figure 6. Air bag contact points.



Figure 7. Blood stain on the front right shoulder belt.

MANUAL RESTRAINT SYSTEMS

The Geo Metro was equipped with 3-point manual belt systems for the four outboard seated positions. The front belt systems consisted of continuous loop belt webbings with sliding latchplates. The inertia activated retractors were mounted in the lower aspect of the B-pillars. The front right and rear retractors were equipped with switchable modes to secure child safety seats. Both front seat D-ring positions were fixed.

The front left belt webbing and buckle assembly were stained with blood. In addition, a subtle D-ring transfer was noted to the driver's shoulder belt webbing. This, in combination with the blood stains, verified the EMT statements which support belt usage.

The front right passenger shoulder belt webbing was stained with blood at the lower segment above the buckle assembly. Similar stains were noted to the buckle at the release button. Superficial air bag fabric

transfers were noted to the belt webbing in the area that would have extended over the chest area of the passenger. There was no loading evidence on the front right belt system.

AUTOMATIC RESTRAINT SYSTEM

The Geo Metro was equipped with a Supplemental Inflatable Restraint (SIR) system that consisted of frontal air bags for the driver and front right passenger positions (**Figure 8**), a single point sensing and diagnostic (SDM) module with an external sensor mounted to the center radiator support panel, and a instrument panel air bag indicator lamp. The front mounted satellite crash sensor was rotated slightly vertically due to displacement of the upper radiator support panel. There was no damage to the sensor housing. The sensor was identified by the following on a bar coded label: 195524NM3.



Figure 8. Deployed frontal air bags.

The front left air bag (**Figure 9**) was concealed within the module assembly of a four spoke steering wheel rim and deployed from asymmetrical H-configuration cover flaps. The upper flap measured 15.5 cm (6.1 in) in width and 5.5 cm (2.2 in) in height. The inside surface of the upper flap displayed the identification number 2C1MR2260S6789214. The lower flap measured 15.5 cm (6.1 in) in width and 8.0 cm (3.1 in) in maximum height. Contact evidence was not present to the face or underside of the air bag module cover flaps.



Figure 9. Deployed front left air bag.

The deployed front left air bag was tethered by two straps which were located at the 3 and 9 o'clock positions. Two vent ports were located at the 10 and 2 o'clock positions on the back side of the bag. The overall diameter of the front left air bag in its deflated state was 62.2 cm (24.5"). The air bag was distinguished by the following identification numbers:

PE5114100-01
TBS5157B0181

Contact evidence on the deployed air bag membrane consisted of several blood spatters which probably resulted from the driver's epistaxis, post-crash.

The front right air bag module assembly was housed in a top-mounted position in the right upper instrument panel. The single cover flap was rectangular in shape, measuring 37.6 cm (14.8") wide and 11.2 cm (4.4") in depth. The air bag was not equipped with internal tethers or vent ports. Venting was achieved through a porous membrane or back vented through the inflator assembly. The rearward excursion of the bag membrane from the leading edge of the cover flap was 68.6 cm (27.0"). With the front right seat track adjusted to a forward position at crash, the bag excursion was 2.5 cm (1.0") from the seat back. The overall dimensions of the front right air bag were 44.4 cm (17.5") in width and 53.3 cm (21.0") in height.

Several areas of vinyl were transferred onto the front right air bag from its restricted deployment path by the forward positioned passenger. The vinyl occurred from its expansion against the module assembly. A band-like transfer was noted to the back side of the bag as documented in **Figure 10**. The front right air bag contained three small tears to the membrane. These appeared to be deployment related from expansion against the interior surfaces of the module assembly and/or the leading edge of the cover flap.




Figure 10. Band-like vinyl transfer to the back side of the front right air bag .



Figure 11. Additional warning label on the front left module cover.

The Geo Metro was equipped with the OEM warning labels affixed to the face of the sunvisors. These labels read as follows:

**CAUTION
TO AVOID SERIOUS INJURY**

For maximum safety protection in all types of crashes, you must always wear your safety belt.

Do not install rearward-facing child seats in any front passenger seat position.

Do not sit or lean unnecessarily close to the air bag.

Do not place any objects over the air bag or between the air bag and yourself.

See the owner's manual for further information and explanations.

Additional air bag warning labels (**Figure 11**) were affixed to both the module cover flaps of the frontal

driver and passenger air bag module assemblies. These labels were forwarded to the owner as a safety awareness campaign by the automobile manufacturers. These updated labels read as follows:

DEATH or SERIOUS INJURY can occur

- Children 12 and under can be killed by the air bag.
- The BACK SEAT is the SAFEST place for children.
- NEVER put a rear-facing child seat in the front.
- ALWAYS use SEAT BELTS and CHILD RESTRAINTS.

DRIVER DEMOGRAPHICS

Age/Sex: 69 year old male
 Height: 170 cm (67")
 Weight: 70 kg (155 lb)
 Manual Restraint
 Usage: 3-point lap and shoulder belt system
 Usage Source: Vehicle inspection, EMT observations at scene
 Eyewear: Unknown
 Vehicle Familiarity: 2.5 years
 Route Familiarity: Very frequent travel
 Type of Medical
 Treatment: None

DRIVER INJURIES

Injury	Injury Severity (AIS 90)	Injury Mechanism
Nasal abrasions with epistaxis (nose bleed)	Minor (290202.1,4)	Front left air bag

DRIVER KINEMATICS

The driver of the Geo Metro was seated in an upright attitude with the seat adjusted to a rear track position (**Figure 12**), set 6.0 cm (2.4") forward of the rear most position and 14.5 cm (5.7") forward of the full forward position. The seat back support was reclined to an angle of 20 degrees. He was wearing the manual 3-point lap and shoulder belt system. Belt usage was supported by blood stains on the latchplate, faint loading marks on the webbing, and observation of the EMTs as they arrived on-scene.



Figure 12. Profile view of the driver’s position.

The driver probably had both hands positioned on the steering wheel rim as he steered right and braked to avoid the dogs. At impact, he initiated a forward trajectory and loaded the deployed front left air bag. His loading against the air bag

resulted in nasal abrasions with epistaxis. He rebounded into the seat back where he came to rest in an upright attitude.

FRONT RIGHT PASSENGER DEMOGRAPHICS

Age/Sex: 55 year old female
 Height: 155 cm (61")
 Weight: 59 kg (130 lb)
 Manual Restraint
 Usage: 3-point lap and shoulder belt
 Usage Source: Vehicle inspection, observations of the EMTs
 Mode of Transport
 From Scene: Ambulance
 Medical Treatment: Transported to a local hospital and transferred via helicopter to a major medical facility that was equipped to treat her spinal cord injury

FRONT RIGHT PASSENGER INJURIES

Injury	Injury Severity (AIS 90)	Injury Mechanism
C6/C7 fracture dislocation with complete quadriplegia and disruption of the disk space and the superior and spinous ligaments with anterior displacement (Note: radiology reports identified a comminuted fracture of the vertebral body of C6 with a fracture of the spinous process of C6 with inferior displacement)	Critical (640228.5,6)	Expanding front right air bag
Multiple bilateral rib fractures with pulmonary edema and pleural effusions	Moderate (450220.2,3)	Expanding front right air bag
Contusions with abrasions over the left upper arm	Minor (790402.1,2; 790202.1,2)	Expanding front right air bag
Contusions with abrasions over the right forearm	Minor (790402.1,1; 790202.1,1)	Expanding front right air bag

** All injuries were documented from the hospital medical records.*

FRONT RIGHT PASSENGER KINEMATICS

The medical records indicated the front right passenger was intoxicated with a BAC of .171. She was presumed to have been in an upright seated position with the seat track adjusted to a forward position and the seat back reclined to 34 degrees. In this adjusted track position, the leading edge of the seat cushion was 5.1 cm (2.0") rearward of the vertical profile of the mid instrument panel. The passenger was restrained by the manual 3-point lap and shoulder belt system. Belt usage was supported by observations of the EMTs as they arrived on-scene, blood stains on the shoulder belt webbing, and air bag membrane transfers on the webbing surface.

Prior to the impact sequence, the passenger noticed several dogs encroaching into the Geo's path of travel. She reportedly (by the driver) reacted by raising her arms with her forearms facing the front of the vehicle. At this point in time, the driver took avoidance action to the animals by swerving to the right and braking to avoid the dogs. This action probably displaced the forward seated passenger in a forward direction and slightly to the left as the seatbelt's retractor locked. The vehicle subsequently departed the roadway and impacted the rock embankment. As a result of the impact, the frontal air bag system deployed. The air bag probably deployed late in the crash sequence due to the underriding damage from the overhanging rock structure.

The forward positioned passenger was within the deployment path (**Figure 13**) of the non-tethered front right air bag. The bag membrane initially expanded against the extended arms of the passenger which resulted in bilateral abrasions and contusion. The bag displaced her arms rearward as the passenger moved forward into the expanding air bag as she responded to the frontal impact force. The combination of bag and belt loading compressed the passenger chest which resulted in multiple bilateral rib fractures (unspecified ribs) with plural edema. Tissue fragments (**Figure 14**) were present on the face of the bag at the lower right quadrant. This tissue transfer resulted from the arm contact as the passenger had no other soft tissue injury.



Figure 13. Deployment of the front right air bag from the top mount position.




Figure 14. Tissue fragments on the lower right aspect of the bag membrane.

The passenger's arm(s), loaded by the force of the deploying air bag, were subsequently displaced upward and rearward toward her face. She sustained epistaxis (nose bleed) from arm contact to her face and hyper-extension of the neck which resulted in a fracture of the C6 vertebral body with anterior displacement of C6 on C7 with quadriplegia. Disruption of the anterior, superior and interspinous ligaments was also present.

The expansion of the air bag membrane against the front right passenger altered the normal deployment path of the bag. A large vinyl transfer was noted to the mid lower aspect of the bag from restricted expansion within the module assembly. The bag membrane was displaced forward into the windshield as evidence by a fabric transfer to the glazing. A similar whitish transfer was noted to the right door panel, surrounding the door release lever and the pull handle.

The passenger was displaced rearward and left by the bag expansion. She came to rest against the driver who held her as she remained alert and oriented while witnesses reportedly stabilized her until EMTs arrived on-scene approximately 15 minutes post-crash.

MEDICAL TREATMENT

The passenger was transported to a local hospital where she was stabilized and diagnosed with the cervical injuries. The hospital staff prepared her for helicopter transfer to a medical facility which was better equipped to treat her spinal injuries. She underwent anterior C6 corpectomy and C5-C7 arthrodesis and posterior spinal fusion and lateral mass plate fixation of C5-C7. She was ventilator dependant and remained hospitalized for 40 days. The passenger was transferred to a rehabilitation facility where she received seven days of treatment. Respiratory complications developed as a result of the cervical cord injury and she was returned to the hospital. She expired 149 days following the crash due to respiratory complications.

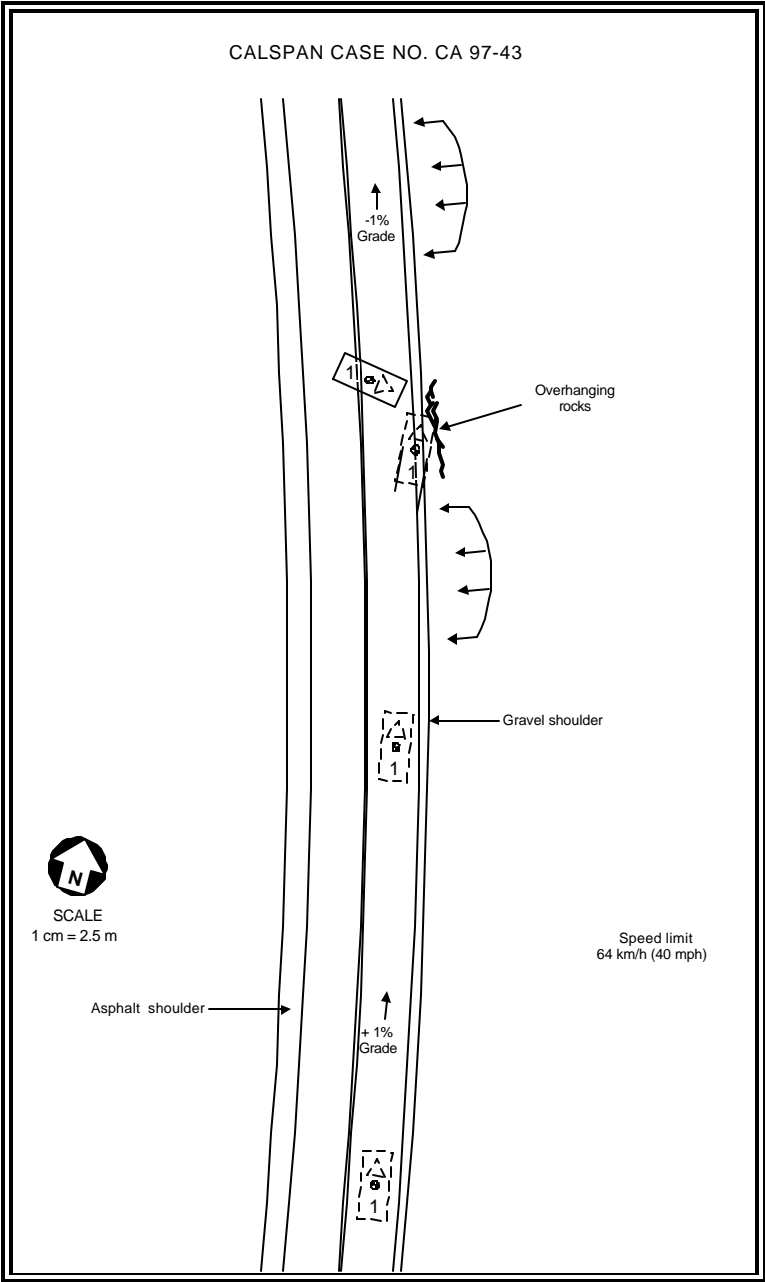


Figure 15. Crash Schematic