



# INDIANA UNIVERSITY

## TRANSPORTATION RESEARCH CENTER

School of Public and Environmental Affairs  
222 West Second Street  
Bloomington, Indiana 47403-1501  
(812) 855-3908 Fax: (812) 855-3537

## REMOTE CHILD AIR BAG-RELATED FATALITY INVESTIGATION

CASE NUMBER - IN-03-030  
LOCATION - New York  
VEHICLE - 1995 FORD ESCORT  
CRASH DATE - June 2001

Submitted:  
May 19, 2004  
Revised:  
February 20, 2008



Contract Number: DTNH22-01-C-07022

Prepared for:

U.S. Department of Transportation  
National Highway Traffic Safety Administration  
National Center for Statistics and Analysis  
Washington, D.C. 20590-0003

## **DISCLAIMERS**

This document is disseminated under the sponsorship of the Department of Transportation in the interest of information exchange. The United States Government assumes no responsibility for the contents or use thereof.

The opinions, findings, and conclusions expressed in this publication are those of the authors and not necessarily those of the National Highway Traffic Safety Administration.

The crash investigation process is an inexact science which requires that physical evidence such as skid marks, vehicular damage measurements, and occupant contact points be coupled with the investigator's expert knowledge and experience of vehicle dynamics and occupant kinematics in order to determine the pre-crash, crash, and post-crash movements of involved vehicles and occupants.

Because each crash is a unique sequence of events, generalized conclusions cannot be made concerning the crashworthiness performance of the involved vehicle(s) or their safety systems.

**Technical Report Documentation Page**

1. <i>Report No.</i> IN-03-030		2. <i>Government Accession No.</i>		3. <i>Recipient's Catalog No.</i>	
4. <i>Title and Subtitle</i> Remote Child Air Bag-Related Fatality Investigation Vehicle - 1995 Ford Escort Location - New York			5. <i>Report Date:</i> May 19, 2004		
			6. <i>Performing Organization Code</i>		
7. <i>Author(s)</i> Special Crash Investigations Team #2			8. <i>Performing Organization Report No.</i>		
9. <i>Performing Organization Name and Address</i> Transportation Research Center Indiana University 222 West Second Street Bloomington, Indiana 47403-1501			10. <i>Work Unit No. (TRAIS)</i>		
			11. <i>Contract or Grant No.</i> DTNH22-01-C-07002		
12. <i>Sponsoring Agency Name and Address</i> U.S. Department of Transportation (NRD-32) National Highway Traffic Safety Administration National Center for Statistics and Analysis Washington, D.C. 20590-0003			13. <i>Type of Report and Period Covered</i> Technical Report Crash Date: June 2001		
			14. <i>Sponsoring Agency Code</i>		
15. <i>Supplementary Notes</i> Remote child air bag-related fatality investigation involving a 1995 Ford Escort with dual frontal air bags, automatic motorized torso and manual lap safety belts, that impacted a 1993 Geo Tracker.					
16. <i>Abstract</i> This report covers a remote investigation of an air bag deployment crash involving a 1995 Ford Escort station wagon (case vehicle) and a 1993 Chevrolet Geo Tracker SUV (other vehicle). This crash is of special interest because the case vehicle's unrestrained front right passenger (5-year-old female) sustained critical head and cervical spine injuries from her deploying front right passenger air bag, resulting in her death. The case vehicle was traveling southward in the southbound lane of a two-lane state highway. The other vehicle was stopped, heading south in the same lane of the same roadway, waiting to make a left turn. The case vehicle's driver observed the threat ahead, steered right and braked with lockup. The case vehicle's front left corner impacted the other vehicle's back right corner, causing the case vehicle's driver and front right passenger air bags to deploy. The case vehicle was deflected to the right and came to rest on the right (west) shoulder a short distance from the point of impact. The other vehicle was pushed slightly forward and leftward and the driver drove forward, bringing the Geo to a controlled stop on the left (east) shoulder. The case vehicle's unrestrained front right passenger moved leftward and forward in response to the unsuccessful avoidance maneuvers and she was struck by the deploying front right passenger's air bag. The front right passenger sustained numerous brain and cervical spine injuries, and other injuries, and was pronounced dead five days post-crash. The restrained case vehicle driver (35-year old male) was not injured. The restrained back left passenger (28-year-old female) sustained a contusion on her head and was transported via ambulance. The restrained back center passenger (4-year-old female) and the back right passenger (less than 1-year-old male), who was restrained in a forward facing child safety seat, did not sustain any apparent injuries but both were transported via ambulance.					
17. <i>Key Words</i> Air Bag Deployment			Motor Vehicle Traffic Crash Injury Severity		18. <i>Distribution Statement</i> General Public
19. <i>Security Classif. (of this report)</i> Unclassified	20. <i>Security Classif. (of this page)</i> Unclassified	21. <i>No. of Pages</i> 9	22. <i>Price</i> \$5,100		

TABLE OF CONTENTS

IN-03-030


	<u>Page No.</u>
BACKGROUND . . . . .	1
CRASH CIRCUMSTANCES . . . . .	1
CASE VEHICLE: 1995 FORD ESCORT STATION WAGON . . . . .	1
AUTOMATIC RESTRAINT SYSTEM . . . . .	2
CASE VEHICLE FRONT RIGHT PASSENGER'S KINEMATICS . . . . .	3
FRONT RIGHT PASSENGER'S INJURIES . . . . .	4
CASE VEHICLE DRIVER'S KINEMATICS . . . . .	6
CASE VEHICLE BACK LEFT PASSENGER'S KINEMATICS . . . . .	6
REAR LEFT PASSENGER'S INJURIES . . . . .	7
CASE VEHICLE BACK CENTER PASSENGER'S KINEMATICS . . . . .	7
CASE VEHICLE BACK RIGHT PASSENGER'S KINEMATICS . . . . .	7
OTHER VEHICLE: 1995 CHEVROLET GEO TRACKER . . . . .	8
SCENE DIAGRAM . . . . .	9
 SELECTED PHOTOGRAPHS	
Figure 1: Case vehicle's southbound approach . . . . .	1
Figure 2: Case vehicle's front and left side at final rest . . . . .	2
Figure 3: Closeup of case vehicle's front left corner . . . . .	2
Figure 4: Case vehicle's driver air bag and automatic safety belt . . . . .	2
Figure 5: Case vehicle's front right passenger air bag and automatic safety belt . . . . .	3
Figure 6: Other vehicle's back and right side at final rest . . . . .	8
Figure 7: Closeup of other vehicle's back right corner . . . . .	8

This report was brought to the NHTSA's attention in June 2003 through a review of the 2001 Fatality Analysis Reporting System (FARS) data. This crash involved a 1995 Ford Escort station wagon (case vehicle) and a 1993 Chevrolet Geo Tracker (other vehicle). The crash occurred in June 2001, at 3:58 p.m., in New York, and was investigated by the applicable municipal police department. This crash is of special interest because the case vehicle's unrestrained front right passenger (5-year-old female, white, unknown if Hispanic) sustained critical head and cervical spine injuries from her deploying front right passenger air bag, resulting in her death. This report is based on the police crash report, police on-scene photographs, autopsy information for the fatal victim and this contractor's evaluation of the available evidence.

### CRASH CIRCUMSTANCES

The case vehicle was traveling southward in the southbound lane of a two-lane state highway and was approaching a three-leg intersection, intending to continue southward. The other vehicle was stopped, heading south in the same lane of the same roadway, waiting to make a left turn and travel east on the intersecting local road. It was daylight, the weather was clear and the asphalt road surface was dry and free of defects. The police reconstructionists reported that the coefficient of friction was measured as 0.77. There were no traffic controls for north-south traffic, except that the area was a no passing zone. The speed limit was 64 km.p.h. [40 m.p.h.]. The case vehicle's driver observed the threat ahead, steered to his right and braked with lockup, depositing 11.5 meters [37.6 feet] of braking skid marks. The crash occurred in the southbound lane, within the intersection.

The case vehicle's front left corner impacted the other vehicle's back right corner, causing the case vehicle's driver and front right passenger air bags to deploy. The case vehicle was deflected to the right and came to rest on the right (west) shoulder a short distance from the point of impact. The other vehicle was pushed slightly forward and leftward and the driver drove beyond the intersection and brought the Geo to a controlled stop on the left (east) shoulder (**Figure 1**).



### CASE VEHICLE

The case vehicle was a 1995 Ford Escort front wheel drive, four-door, five-passenger station wagon (VIN: 1FASP15J0SW-----), equipped with a 1.9 liter I4 gasoline engine and an automatic transmission with a console-mounted selector lever, and was not equipped with anti-lock brakes. The Escort was fitted with motorized automatic shoulder belts with manual lap belts and frontal air bags for the two front seat positions. The odometer reading is not known. The Escort's wheelbase was 250 centimeters [98.4 inches]. The Escort was towed due to disabling damage.

The case vehicle sustained narrow direct contact damage at the front left corner (**Figures 2 and 3**), with crushing above the bumper and relatively light scraping on the bumper yielding a front underride damage configuration. The left headlight lens was fractured and the headlamp/turn signal assembly was displaced but not broken away. The left fender was crushed rearward and slightly inward, and the leading edge of the hood was crushed rearward and downward. The left fender showed induced buckling rearward of the wheel well. The left front wheel was restricted due to the crushed fender being pressed against it, but with no obvious damage to the tire and no damage or restriction on any other wheel or tire. There were cracks in the lower center windshield glazing and no other glazing damage.



**Figure 2:** Case vehicle's front and left side, at final rest (case photo #10)



**Figure 3:** Case vehicle's direct damage at front left corner (case photo #11)

The CDC for the case vehicle's single impact was estimated from photographs as **12-FLEE-2 (350)**. The WinSMASH reconstruction program, damage algorithm with CDC only for both vehicles, was used. The total, longitudinal and lateral delta Vs are, respectively: 13.0 km.p.h. [8.1 m.p.h.], -12.8 km.p.h. [-7.9 m.p.h.], + 2.3 km.p.h. [+ 1.4 m.p.h.]. This is a borderline reconstruction and the results appear somewhat low but reasonable. This was a crash of low severity (14-23 km.p.h. [9-14 m.p.h.]) for the case vehicle.

#### **AUTOMATIC RESTRAINT SYSTEM**

The case vehicle was equipped with frontal air bags and motorized two-point automatic shoulder safety belts at the driver and front right passenger seat positions.

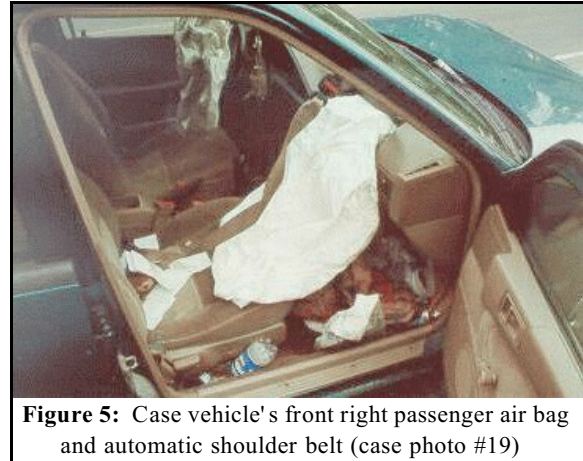
The driver's air bag was located in the steering wheel hub with cover flap(s) in an unknown configuration. The deployed air bag was round with the diameter not known (**Figure 4**). It is not known if the driver's air bag was designed with any tether(s) or vent port(s). There was no obvious damage to the air bag, and there was no evidence of occupant contact visible in the available photographs.



**Figure 4:** Driver's air bag and automatic shoulder belt (case photo #16)

The driver's automatic safety belt consisted of a shoulder belt attached to a retractor in the center console and a latch attached to a buckle that moves via a motorized track along the upper door frame. The available photographs show the case vehicle with the driver's door open but with the buckle in the closed position, indicating a possible malfunction of the motorized component of the automatic safety belt system (**Figure 4**). It is not known whether this possible malfunction was a result of the crash. The safety belt webbing appears to be correctly retracted into its center console retractor.

The front right passenger's air bag was located in the top of the right instrument panel with a single cover flap. The deployed air bag was probably rectangular, with unknown dimensions (**Figure 5**). It is not known if the front right passenger's air bag was designed with any tether(s) or vent port(s). There was no obvious damage to the air bag, and no evidence of occupant contact visible in the available photographs.



**Figure 5:** Case vehicle's front right passenger air bag and automatic shoulder belt (case photo #19)

The front right passenger's automatic safety belt consisted of the same components as the driver's automatic safety belt. The available photographs show the case vehicle with the front right passenger's door open and with the motorized buckle in the forward position (**Figure 5**). The safety belt webbing is twisted, indicating that it had been disconnected and incorrectly reconnected. The webbing also shows a substantial amount of slack, indicating that the retractor in the center console was not functioning properly or a twist in the belt at the retractor may have prevented full retraction of the belt. It is not known if the incorrect configuration of the webbing and the possibly malfunctioning retractor were a result of the crash, but the police crash report notes that there was no evidence of loading stress on any component of the front right passenger's automatic safety belt system.

#### **CASE VEHICLE FRONT RIGHT PASSENGER'S KINEMATICS**

The front right passenger (5-year-old female, white, unknown if Hispanic, 114 centimeters, 21 kilograms [45 inches, 46 pounds]) was not using the available, manual, two-point lap belt, and was not restrained by the automatic, motorized, two-point shoulder belt. The police crash report notes that there was no evidence of use on any component of the front right safety belt system. In addition, her injuries and kinematics indicate that she was not restrained. Her seat adjustments are not known, but the available photographs show the seat back slightly reclined and the seat track toward the rear. There is no information about her pre-crash posture, but she was probably seated in a forward facing position with the manual lap belt not fastened and the automatic shoulder belt behind her back.

The driver observed the stopped vehicle ahead and steered right and braked with lock-up. The front right passenger moved leftward and forward in response to these avoidance maneuvers.

The case vehicle's impact with the other vehicle caused the child, who was now out of position, to move further forward, and caused the case vehicle's front right passenger's air bag to deploy. Her arms flailed and her right arm was struck by the deploying air bag module cover flap, causing a fracture of her right forearm. She encountered the deploying air bag with her face, neck and chest. Her interaction with the air bag caused: atlanto-occipital dislocation with contusion of the cervical spinal cord; diffuse axonal injury to the medulla oblongata; brain stem hemorrhage; subarachnoid hemorrhage over the midbrain and pons; cerebral edema with flattening of the gyri and obliteration of the sulci; loosening of the lower left medial incisor; laceration of the upper frenulum and contusion of the upper lip; abrasions on the right mandible and under the chin; abrasions across the upper chest; and contusions to both lungs. The police reconstructionists presented a scenario that has the child being lifted by the air bag and propelled rearward through the gap between the two front bucket seats into the back seat, with the child's head striking the back left passenger's head. This scenario cannot be confirmed. The left side of her abdomen struck the driver's seat back and she sustained a contusion of the spleen. Her right leg struck the front right seat back, causing contusions on the right thigh. Her position at final rest is not known.

**CASE VEHICLE FRONT RIGHT PASSENGER'S INJURIES**

The front right passenger was transported via ambulance to a local hospital and she was subsequently transferred to a trauma center. Her medical treatment records were not acquired. She was pronounced dead five days post-crash and was autopsied.

Injury Number	Injury Description (including Aspect)	NASS Injury Code & AIS 90	Injury Source (Mechanism)	Source Confidence	Source of Injury Data
	Nonanatomic brain injury with loss of consciousness involving six-day period	Not coded	Air bag, front right passenger's	Probable	Autopsy
1 2	Diffuse axonal injury medulla oblongata with softness <sup>1</sup> and brain stem hemorrhage with hemorrhage along left basal ganglia and subarachnoid hemorrhage over midbrain and pons	critical 140206.5,8 140210.5,8	Air bag, front right passenger's	Probable	Autopsy
3	Contusion, 0.6 cm (0.25 in) left parietal lobe, not further specified	serious 140606.3,2	Unknown contact mechanism	Unknown	Autopsy
4	Diffuse axonal injury periventricular, not further specified	critical 140628.5,9	Air bag, front right passenger's	Probable	Autopsy
5	Hemorrhage, subdural, 15 cc, bilaterally, forming thin layer	critical 140654.5,3	Air bag, front right passenger's	Possible	Autopsy

<sup>1</sup> Medulla oblongata fell apart while removing during autopsy.



Injury Number	Injury Description (including Aspect)	NASS Injury Code & AIS 90	Injury Source (Mechanism)	Source Confidence	Source of Injury Data
6	Cerebral edema with flattening of gyri and obliteration of sulci <sup>2</sup> , not further specified and without mention of effect on the ventricles or brain stem cisterns <sup>3</sup>	serious 140660.3,9	Air bag, front right passenger's	Probable	Autopsy
7	Hemorrhage within the ventricular system (intraventricular), not further specified	severe 140678.4,9	Air bag, front right passenger's	Probable	Autopsy
8	Contusions, several, bilateral lungs on periphery	severe 441410.4,3	Air bag, front right passenger's	Probable	Autopsy
9	Contusion spleen, 2.5 cm (1 in) with intraparenchymal, subcapsular hemorrhage upper pole	moderate 544212.2,2	Seat back, driver's	Possible	Autopsy
10	Contusion cervical spinal cord (i.e., diffuse epidural hemorrhage surrounding cervical cord with softness to upper cord)	serious 640200.3,6	Air bag, front right passenger's	Probable	Autopsy
11	Dislocation atlanto-occipital, not further specified	moderate 650208.2,6	Air bag, front right passenger's	Probable	Autopsy
12	Fracture (clinical) right forearm, not further specified	moderate 751900.2,1	Front right module's cover flap	Possible	Autopsy
13	Dislocation (loose) left lower medial incisor	minor 251402.1,8	Air bag, front right passenger's	Probable	Autopsy
14	Laceration {tear}, 0.3 cm (0.125 in) upper frenulum	minor 243204.1,8	Air bag, front right passenger's	Probable	Autopsy
15	Contusion {ecchymosis} buccal mucosa upper lip	minor 243202.1,8	Air bag, front right passenger's	Probable	Autopsy
16	Abrasion, 1 cm (0.375 in) near right angle of mandible	minor 290202.1,1	Air bag, front right passenger's	Probable	Autopsy

<sup>2</sup> The following terms are defined in DORLAND' S ILLUSTRATED MEDICAL DICTIONARY as follows:

**fissure (fish'ar):** any cleft or groove, normal or otherwise; especially a deep fold in the cerebral cortex which involves the entire thickness of the brain wall. Compare *sulcus*.

**gyrus (jī'ras) pl. gyri (jī'ri):** one of the convolutions of the surface of the brain caused by infolding of the cortex; see *gyri cerebri*.

**g. cerebrāles:** cerebral gyri; the tortuous convolutions of the surface of the cerebral hemisphere, caused by infolding of the cortex and separated by the fissures or sulci. Many are constant enough that they have been given special names. Called also *gyri cerebri* and *gyri of cerebrum*.

**g. cē'rebri, gyri of cerebrum:** gyri cerebrales.

**sulcus (sul'kas) pl. sul'ci (sul'si):** a groove, trench, or furrow; a general term for such a depression, especially one of those on the surface of the brain, separating the gyri. Compare *fissure*.

<sup>3</sup> Intracranial pressure tubes were placed bilaterally in parietal regions.

Injury Number	Injury Description (including Aspect)	NASS Injury Code & AIS 90	Injury Source (Mechanism)	Source Confidence	Source of Injury Data
17	Abrasion, 6.4 x 0.6 cm (2.5 x 0.25 in) midline, undersurface of chin, transversely oriented	minor 290202.1,8	Air bag, front right passenger's	Probable	Autopsy
18	Abrasion, 1 cm (0.375 in) mid right clavicle	minor 790202.1,1	Air bag, front right passenger's	Probable	Autopsy
19	Contusion {ecchymosis}, 8.9 x 3.8 cm (3.5 x 1.5 in), left upper chest	minor 490402.1,2	Air bag, front right passenger's	Possible	Autopsy
20	Contusion {ecchymosis}, 5.1 x 2.5 cm (2 x 1 in) medial, mid right thigh	minor 890402.1,1	Seat back, front right passenger's	Possible	Autopsy

#### CASE VEHICLE DRIVER'S KINEMATICS

The case vehicle's driver (35-year-old male, race/ethnicity unknown, height and weight unknown) was reported as having been restrained by his available, manual, two-point lap safety belt and the automatic, motorized, two point shoulder belt. His seat adjustments and seated posture are not known, but he was probably in a normal driving posture.

The driver observed the stopped vehicle ahead and steered right and braked with lockup. He moved slightly leftward and forward in response to these avoidance maneuvers. The front of the case vehicle impacted the back of the other vehicle, causing the case vehicle's driver and front right passenger air bags to deploy and causing the driver to move forward and slightly upward. The driver encountered the air bag with his chest and rebounded into his seat. The driver was police-reported as not sustaining any injuries and was not transported by ambulance.

#### CASE VEHICLE BACK LEFT PASSENGER'S KINEMATICS

The back left passenger (28-year-old female, race/ethnicity unknown, height and weight unknown) was reported as having been restrained by the lap portion of the available, manual, three-point lap-and-shoulder safety belt system. Her seat back and seat track were not adjustable. She was probably in a normal, forward-facing seated position.

The driver observed the stopped vehicle ahead and steered right and braked with lockup. The back left passenger moved slightly leftward and forward in response to these avoidance maneuvers. The front of the case vehicle impacted the back of the other vehicle and the back left passenger moved further forward and slightly upward. The police reconstructionists presented a scenario that has the front right passenger being lifted by the front right air bag and propelled rearward through the gap between the two front bucket seats into the back seat, with the child's head striking the back left passenger's head. This scenario cannot be confirmed. The back left

passenger's position at final rest is not known. The back left passenger was police-reported as having sustained a contusion on her head. She was transported via ambulance to a local hospital. Her treatment status and specific injuries are not known.

**BACK LEFT PASSENGER'S INJURIES**

The police crash report coding blocks indicate that the back left passenger sustained a contusion on the head and was conscious, with further details not known.

Injury Number	Injury Description (including Aspect)	NASS Injury Code & AIS 90	Injury Source (Mechanism)	Source Confidence	Source of Injury Data
1	“Contusion to the head” NFS	minor 190402.1,9	unknown	unknown	Police crash report

**CASE VEHICLE BACK CENTER PASSENGER'S KINEMATICS**

The case vehicle's back center passenger (4-year-old female, race/ethnicity unknown, height and weight unknown) was reported as having been restrained by the available manual lap belt. Her seat back and seat track were not adjustable. There is no knowledge of her seated posture, but she was probably in a normal, forward-facing seated position.

The driver observed the stopped vehicle ahead and steered right and braked with lockup. The back center passenger moved slightly leftward and forward in response to these avoidance maneuvers. At impact, the back center passenger moved further forward and slightly upward. The police report indicates that this child did not sustain any injuries. She was transported via ambulance to a local hospital. Her treatment status and specific injuries, if any, are not known.

**CASE VEHICLE BACK RIGHT PASSENGER'S KINEMATICS**

The case vehicle's back right passenger (less than one-year-old male, race/ethnicity unknown, height and weight unknown) was seated in a forward facing convertible child safety seat with a three-point harness and a tray shield. The available photos show the vehicle's manual, three point, lap-and-shoulder safety belt system with the shoulder portion pulled taut and passing behind the child safety seat, with further details concerning the child safety seat installation and the child's restraint status not known.


The driver observed the stopped vehicle ahead and steered right and braked with lockup. The back right passenger moved slightly leftward and forward in response to these avoidance maneuvers. At impact, the back right passenger moved further forward and slightly upward. The police report indicates that this child did not sustain any injuries. He was transported via ambulance to a local hospital. His treatment status and specific injuries, if any, are not known.

The other vehicle was a 1993 Chevrolet Geo Tracker four wheel drive, two-door, four-passenger convertible sport utility vehicle (VIN: 2CNBJ18U6P6-----), equipped with a 1.6 liter I4 gasoline engine and a manual transmission with a floor-mounted shift lever. Its specification wheelbase was 220 centimeters [86.6 inches]. The Geo was towed due to disabling damage.

The Geo sustained narrow direct contact damage on the bumper at the back right corner that exhibited the features of a classic rear override impact (**Figures 6 and 7**). The bumper was abraded and displaced forward. The right rear wheel assembly was pushed forward and inward at the front, suggesting that the rear axle may have been bent. The available photos do not indicate whether the right rear wheel was restricted. The right rear tail light lens was cracked but not broken away. There was minor deformation of the right rear quarter panel.



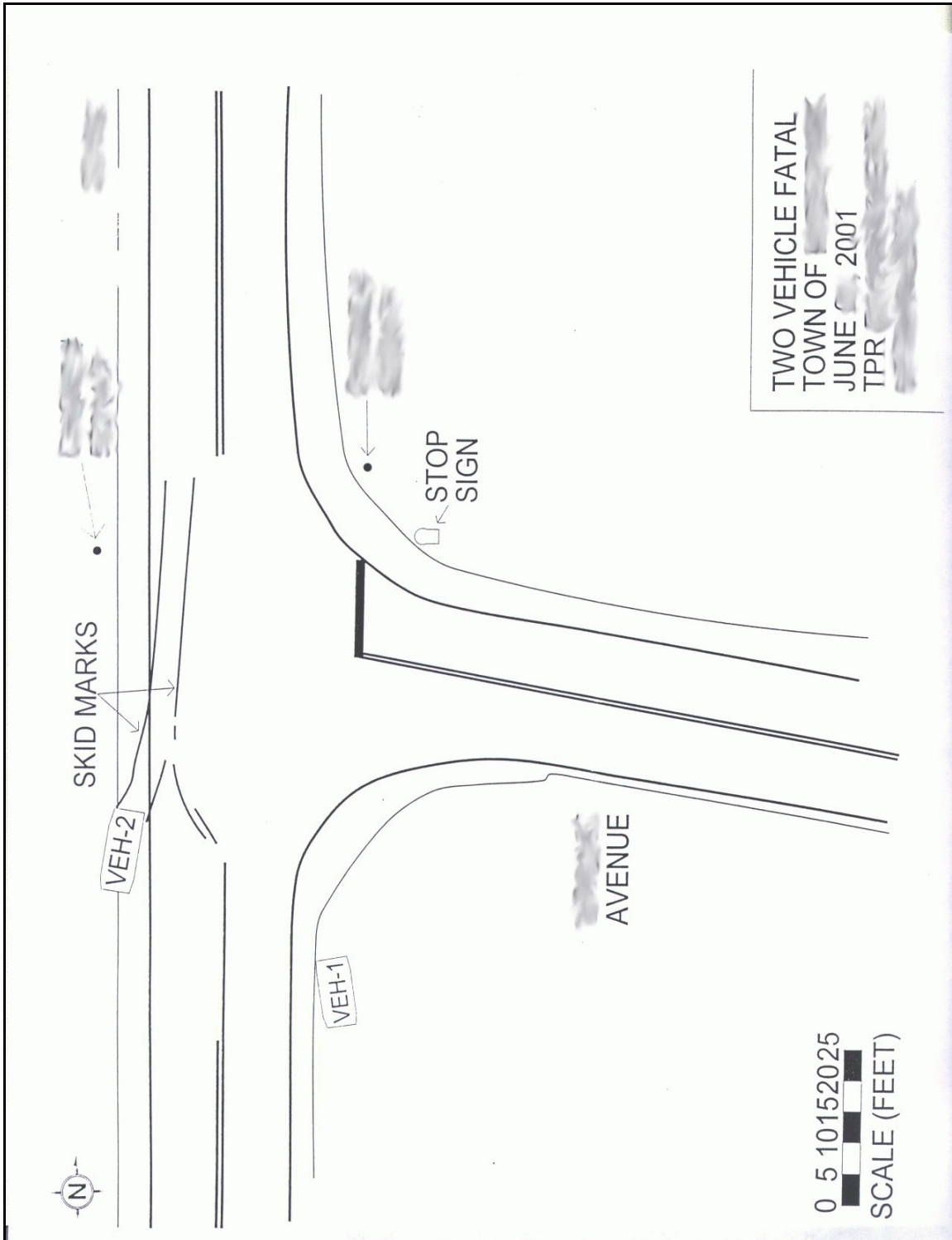
**Figure 6:** Geo at final rest; note override damage at back right corner (case photo #23)



**Figure 7:** Closeup of Geo's back right override damage (case photo #26)

The CDC for the Geo's single impact was estimated from photographs as **06-BRLE-2 (180)**. The WinSMASH reconstruction program, damage algorithm with CDC only for both vehicles, was used. The total, longitudinal and lateral delta Vs for the Geo are, respectively: 14.0 km.p.h. [8.7 m.p.h.], + 14.0 km.p.h. [+ 8.7 m.p.h.], 0 km.p.h. [0 m.p.h.]. This is a borderline reconstruction and the results appear somewhat low but reasonable. This was a crash of low severity (14-23 km.p.h. [9-14 m.p.h.]) for the Geo.

According to the police crash report, the Geo's driver (20-year-old male, race/ethnicity unknown, height and weight unknown) was restrained by his available, manual, three-point, lap-and-shoulder safety belt system. He complained of abdominal pain and was transported by ambulance to a local hospital. His treatment status and specific injuries, if any, are not known. There was no other occupant in the Geo.



note: copied from police crash report, vehicle #2 in this drawing is the case vehicle