

**TRANSPORTATION SCIENCES
CRASH DATA RESEARCH CENTER**

Veridian Engineering
Buffalo, New York 14225

**VERIDIAN ON-SITE AIR BAG RELATED ADULT
DRIVER FATALITY INVESTIGATION**

VERIDIAN CASE NO. CA02-008

VEHICLE - 1998 FORD RANGER XLT

LOCATION - STATE OF ILLINOIS

CRASH DATE - NOVEMBER, 1998

Contract No. DTNH22-01-C-17002

Prepared for:

U.S. Department of Transportation
National Highway Traffic Safety Administration
Washington, D.C. 20590

DISCLAIMER

This document is disseminated under the sponsorship of the Department of Transportation in the interest of information exchange. The United States Government assumes no responsibility for the contents or use thereof.

The opinions, findings, and conclusions expressed in this publication are those of the authors and not necessarily those of the National Highway Traffic Safety Administration.

The crash investigation process is an inexact science which requires that physical evidence such as skid marks, vehicular damage measurements, and occupant contact points are coupled with the investigator's expert knowledge and experience of vehicle dynamics and occupant kinematics in order to determine the pre-crash, crash, and post-crash movements of involved vehicles and occupants.

Because each crash is a unique sequence of events, generalized conclusions cannot be made concerning the crashworthiness performance of the involved vehicle(s) or their safety systems.

TECHNICAL REPORT STANDARD TITLE PAGE

| | | | |
|---|---|---|------------------|
| 1. <i>Report No.</i> CA02-008 | 2. <i>Government Accession No.</i> | 3. <i>Recipient's Catalog No.</i> | |
| 4. <i>Title and Subtitle</i> Veridian On-Site Air Bag Related Adult Driver Fatality Investigation Vehicle - 1998 Ford Ranger XLT Location - State of Illinois | | 5. <i>Report Date:</i> November, 2002 | |
| | | 6. <i>Performing Organization Code</i> | |
| 7. <i>Author(s)</i> Crash Data Research Center | | 8. <i>Performing Organization Report No.</i> | |
| 9. <i>Performing Organization Name and Address</i> Veridian Engineering Transportation Sciences Crash Data Research Center P.O. Box 400 Buffalo, New York 14225 | | 10. <i>Work Unit No.</i> C00410.0000.0022 | |
| | | 11. <i>Contract or Grant No.</i> DTNH22-01-C-17002 | |
| 12. <i>Sponsoring Agency Name and Address</i> U.S. Department of Transportation National Highway Traffic Safety Administration Washington, D.C. 20590 | | 13. <i>Type of Report and Period Covered</i> Technical Report Crash Date - November, 1998 | |
| | | 14. <i>Sponsoring Agency Code</i> | |
| 15. <i>Supplementary Notes</i> On-site investigation of a frontal collision (into a fixed object) that involved a 1998 Ford Ranger XLT pickup truck equipped with redesigned frontal air bags for the driver and front right passenger positions. | | | |
| 16. <i>Abstract</i> This on-site investigation focused on the injury mechanisms that caused the death of a 48 year old restrained female driver of a 1998 Ford Ranger XLT pickup truck. The Ford Ranger pickup truck was equipped with redesigned frontal air bags for the driver and front right passenger positions which deployed as a result of a frontal collision with a concrete base supporting a signpost. The driver of the Ford had Klippel-Feil Syndrome, a rare degenerative disease of the cervical vertebrae that produced a natural fusion of her neck. The driver lived a normal life despite her condition. She was operating the vehicle in a southwesterly direction across a large parking lot when she failed to observe the signpost concrete support base. The front plane impacted the concrete support base resulting in moderate damage. The restrained 48 year old female driver initiated a forward trajectory in response to the 12 o'clock impact force. Her head and upper torso were displaced out-of-position forward by the elongated crash pulse prior to air bag deployment. The expanding driver air bag contacted her under the chin which resulted in abrasions of the chin and anterior neck. The continued expansion of the bag hyper-extended the neck resulting in an unspecified first cervical fracture with associated underlying brain trauma. The driver was transported to a local trauma center and pronounced deceased shortly after arrival. The unrestrained 20 year old male front right passenger also initiated a forward trajectory in response to the 12 o'clock impact force and loaded the knee bolster and deployed redesigned passenger air bag. He was reported by police as uninjured in the crash. | | | |
| 17. <i>Key Words</i> Collision Deformation Classification (CDC): 12-FCEN-2 WinSMASH damage algorithm: 29.2 km/h (18.1 mph) Klippel-Feil Syndrome (<i>pre-existing medical condition</i>) Cervical spine fracture at C1 | | 18. <i>Distribution Statement</i> General Public | |
| 19. <i>Security Classif. (of this report)</i> Unclassified | 20. <i>Security Classif. (of this page)</i> Unclassified | 21. <i>No. of Pages</i> 10 | 22. <i>Price</i> |

TABLE OF CONTENTS

| | |
|---|----|
| BACKGROUND | 1 |
| SUMMARY | |
| Crash Site..... | 1 |
| Pre-Crash | 2 |
| Crash..... | 2 |
| Post-Crash..... | 3 |
| VEHICLE DATA | 3 |
| VEHICLE DAMAGE | |
| Exterior | 3 |
| Interior | 4 |
| MANUAL RESTRAINT SYSTEMS | 5 |
| SUPPLEMENTAL RESTRAINT SYSTEMS..... | 5 |
| Event Data Recorder (EDR)..... | 6 |
| DRIVER DEMOGRAPHICS | 7 |
| Driver Injuries | 7 |
| Driver Pre-Existing Medical Condition | 7 |
| Driver Kinematics | 8 |
| FRONT RIGHT PASSENGER DEMOGRAPHICS | 9 |
| Front Right Passenger Injuries | 9 |
| Front Right Passenger Kinematics | 9 |
| SCENE DIAGRAM..... | 10 |
| 1998 FORD RANGER XLT PICKUP TRUCK ACCELERATION TABLE..... | 11 |

**VERIDIAN ON-SITE AIR BAG RELATED ADULT
DRIVER FATALITY INVESTIGATION
VERIDIAN CASE NO: CA02-008
VEHICLE - 1998 FORD RANGER XLT
LOCATION - STATE OF ILLINOIS
CRASH DATE - NOVEMBER, 1998**

BACKGROUND

This on-site investigation focused on the injury mechanisms that caused the death of a 48 year old restrained female driver of a 1998 Ford Ranger XLT pickup truck (**Figure 1**). The Ford Ranger pickup truck was equipped with redesigned frontal air bags for the driver and front right passenger positions which deployed as a result of a frontal collision with a concrete base supporting a signpost. The driver of the Ford had Klippel-Feil Syndrome, a rare degenerative disease of the cervical vertebrae that produced a natural fusion of her neck. The driver lived a normal life despite her condition. She was



Figure 1 - Overall view of 1998 Ford Ranger pickup.

operating the vehicle in a southwesterly direction across a large parking lot when she failed to observe the signpost concrete support base. The front plane impacted the concrete support base resulting in moderate damage. The restrained 48 year old female driver initiated a forward trajectory in response to the 12 o'clock impact force. Her head and upper torso were displaced out-of-position forward by the elongated crash pulse prior to air bag deployment. The expanding driver air bag contacted her under the chin which resulted in abrasions of the chin and anterior neck. The continued expansion of the bag hyper-extended the neck resulting in an unspecified first cervical fracture with associated underlying brain trauma. The driver was transported to a local trauma center and pronounced deceased shortly after arrival. The unrestrained 20 year old male front right passenger also initiated a forward trajectory in response to the 12 o'clock impact force and loaded the knee bolster and deployed redesigned passenger air bag. He was reported by police as uninjured in the crash.

The crash was identified by NHTSA through a news search and immediately assigned to the Veridian SCI Team as an on-site investigative effort on Friday, February 27, 2002. The on-site investigator departed on Wednesday, March 6th and completed field activities on Thursday, March 7, 2002.

SUMMARY

Crash Site

This single vehicle crash occurred during the evening hours of November, 1998. At the time of the crash, it was dark (parking area lighted) with heavy rain conditions as the roads were wet. The crash occurred in the southwest sector of a large discount store parking lot located north of an adjacent multi-lane urban 4-leg intersection. The (straight/level) asphalt surfaced parking lot was bordered to the east by a fast-food restaurant and to the west by a large discount store with store fronts located approximately 14.7 meters (48.2 feet) west of the parking area. Environmental features included light support poles, shopping cart corrals, and a handicap parking sign with a 16.5 cm (6.5 in) concrete support base. No traffic control was present at the scene which had no regulatory speed limit.

Inclement weather conditions were identified as a major contributing factor in the pre-crash circumstances. Although the passenger reported to police that the vehicle's windshield wipers and headlights were in use prior to the collision, heavy rain may have inhibited ambient lighting of the immediate environment as a build-up of water droplets on the windshield produced excessive glare, thus reducing the driver's field of vision. The scene schematic is included as **Figure 9** at the end of the narrative report.

Pre-Crash

The 48 year old female driver of the 1998 Ford Ranger XLT pickup truck completed her shift at a nearby fast-food restaurant and was giving a co-worker a ride home, operating the vehicle in a southwesterly direction (diagonally) across the large parking area (**Figure 2**). As the vehicle approached the south exit of the parking lot, the driver failed to observe the signpost concrete support base. The police reported no tire marks present at the scene indicative of possible driver avoidance maneuvers.



Figure 2 - Parking lot.

Crash

The front right area of the Ranger impacted the signpost concrete support base (**Figure 3**) which resulted in moderate damage. Impact speeds and velocity changes were computed utilizing the WinSMASH reconstruction program. The trajectory algorithm calculated a speed *at impact* of 38.1 km/h (23.7 mph), as the damage algorithm computed a barrier equivalent velocity change of 29.2 km/h (18.1 mph) with a matching negative longitudinal component. Impact resulted in deployment of the Ford's redesigned frontal air bag system. The



Figure 3 - Impacted pole.

Ford's Event Data Recorder (EDR) logged a longitudinal velocity change of -30.6 km/h (-19.0 mph) and timing of the frontal air bag deployment at 118 milliseconds into the crash event. At this point, the vehicle rebounded approximately 1.5 meters (4.5 feet) coming to rest in close proximity to the point of impact facing south.

Post-Crash

Following the crash, the front right passenger exited the vehicle under his own power through the right door. He subsequently opened the left door, removed the driver and laid her down on the ground adjacent to the final rest position of the vehicle. The passenger then observed the driver unconscious and not breathing, and placed her back into the driver seat of the vehicle. The passenger went into the nearby discount store to summon for help which arrived on-scene within minutes of the crash. The driver was transported by ambulance to a local trauma center and pronounced deceased shortly after arrival. The front right passenger was reported by police as uninjured in the collision. The vehicle was towed from the scene with disabling damage.

VEHICLE DATA

The 1998 Ford Ranger XLT was manufactured in September, 1997 and identified by the vehicle identification number (VIN): 1FTYR10C2WV (production number deleted). The driver's spouse was reported by police as the owner of the vehicle which was a regular cab pickup truck equipped with rear-wheel drive, a 2.5 liter, 4-cylinder engine, and an aftermarket bed cover. At the time of the crash, the odometer had recorded 18,470 km (11,477 miles). The seating was configured with a split bench seat (with folding backs). The family attorney refused the surrogate interview, therefore, previous crashes or maintenance on the Ford's frontal air bag system was unknown.

VEHICLE DAMAGE

Exterior

The 1998 Ford Ranger XLT sustained moderate frontal damage as a result of the impact with the signpost concrete support base (**Figures 4**). The direct contact damage began 58.0 cm (22.8 in) inboard of the front right bumper corner and extended left 17.0 cm (6.7 in). The impact deformed the entire front end width resulting in a combined direct and induced damage length (Field L) of 129 cm (50.8 in). Six crush measurements were documented at the level of the bumper: C1 = 0 cm, C2 = 4 cm (1.6 in), C3 = 17 cm (6.7 in), C4 = 41 cm (16.1 in), C5 = 17 cm (6.7 in), C6 = 4 cm (1.6 in). The Collision Deformation Classification (CDC) for this impact was 12-FCEN-2 with a principal direction



Figure 4 - Damaged 1998 Ford Ranger Pickup.

of force of 0 degrees. The hood was deformed up and rearward from engagement against the support base. The bumper corners were displaced inward due to the narrow contact damage. The right fender was deformed slightly rearward. The left front tire was deflated (not restricted) with abrading to the wheel noted which was attributed to post-crash damage. Pre-existing damage was noted along the right rear side surface. The windshield was fractured at the right lower A-pillar from exterior impact forces (only). No induced roof buckling or wheelbase reduction was identified.

Interior

Interior damage to the Ford Ranger was moderate and was attributed to occupant contact. Scuff marks were documented on the left knee bolster along with a large indentation to the right knee bolster. Deep scratch marks were identified on the (column mounted) transmission selector lever. The rear view mirror was fractured and separated from the windshield. Abrasions and scrub marks were documented on the right sun visor (vanity mirror undamaged). Blood spattering was noted on the headliner adjacent to the left windshield header and right backlight header. Additional blood spattering was noted on the right B-pillar and backlight. No steering wheel rim deformation or column compression was identified; however, the steering mechanism was separated. No component intrusions were found in the vehicle. **Figure 5** is an overall view of the instrument panel.



Figure 5 - Overall view of the instrument panel.

MANUAL RESTRAINT SYSTEMS

The interior of the Ford Ranger consisted of a three passenger seating configuration with a split bench seat (with folding backs). The driver 3-point manual lap and shoulder belt system consisted of a continuous loop belt webbing with a sliding latch plate and a dual mode retractor (inertial lock/belt sensitive). Loading evidence consisted of abrasions to the D-ring and latch plate along with dimpling to the shoulder belt webbing and stretched stitching at the lower restraint anchor attachment point (no energy management loops). The right seating position was equipped with a 3-point manual lap and shoulder belt system which consisted of a continuous loop belt webbing with a sliding latch plate and a retractor equipped with an inertial and switchable lock mechanism. No loading evidence was identified on the right restraint to substantiate usage by this occupant. Slight dimpling was noted to the shoulder portion of the right restraint, however, these marks were attributed to belt stowage rather than occupant loading. In addition, the lack of blood stains to the webbing consistent with blood spattering to the right B-pillar and headliner areas indicated the passenger restraint was in a retracted (stowed) position. The center seat was equipped with a 2-point manual lap belt and a locking latch plate.

SUPPLEMENTAL RESTRAINT SYSTEMS

The 1998 Ford Ranger XLT was equipped with redesigned frontal air bags for the driver and front right passenger positions which deployed as a result of the crash (**Figures 6 and 7**). The driver air bag was housed in the center of the steering wheel with a horizontally oriented flap tear seam (H-configuration). The flaps were rectangular in shape as the upper flap measured 17.0 cm (6.7 in) in width and 6.5 cm (2.6 in) in height while the lower flap measured 17.0 cm (6.7 in) in width and 4.0 cm (1.6 in) in height. No contact evidence was identified on the exterior surface of the module cover flaps. The diameter of the driver air bag measured 63.3 cm (24.9 in) in its deflated state. The air bag

was tethered by two internal straps and vented by two 2.0 cm (0.8 in) ports located at the 11 o'clock and 1 o'clock sectors on the rear aspect of the air bag. Although heavily stained by dirt and mold from exposure to the environment post-crash, inspection of the driver air bag identified a light colored fabric transfer at the lower left quadrant and a dark colored fabric transfer at the mid-right section of the air bag face.

The front right passenger air bag was housed in the right mid-instrument panel area with a single cover flap design hinged at the top aspect. The flap was rectangular in shape and measured 37.0 cm (14.6 in) in width and 17.5 cm (6.9 in) in height. No contact evidence was identified on the exterior surface of the module cover flap. The passenger air bag measured 62.5 cm (24.6 in) in width and 72.5 cm (28.5 in) in height in its deflated state. No vent ports or internal tether straps were present. Also stained by dirt and mold post-crash, contact evidence consisted of a dark blue fabric transfer documented at the upper right quadrant and a light blue fabric transfer which began on the bottom right portion of the membrane and extended into the lower right quadrant of the air bag face. The vehicle was also equipped with a passenger air bag cutoff switch which was set to the air bag "on" position.




Figure 6 – Driver's air bag.



Figure 7 - Passenger's air bag.

Event Data Recorder (EDR)

The 1998 Ford Ranger XLT Event Data Recorder (EDR) was located in the right kick panel (forward of the A-pillar) and capable of recording an acceleration trace after algorithm wake-up for a period of 220 milliseconds, the deployment time, and the faults in the system. This module recorded a maximum longitudinal Delta-V of -30.6 km/h (-19.0 mph) with air bag deployment at 118 milliseconds into the event. There were no recorded faults in the system. The system was equipped with two ball-in-tube sensors located on the upper radiator support. The EDR module and sensors were removed by Ford representatives post-crash for further analysis.

DRIVER DEMOGRAPHICS

Age/Sex: 48 year old female
Height: 65 in (165 cm)
Weight: 65 kg (143 lb)
Seat Track Position: Middle position
Manual Restraint Use: 3-point lap and shoulder belt system
Usage Source: Vehicle inspection, police report
Eyewear: None
Type of Medical Treatment: Transported to a local trauma center and pronounced deceased

Driver Injuries

| <i>Injury</i> | <i>Severity (AIS 90)</i> | <i>Injury Mechanism</i> |
|---|---------------------------------|--------------------------------|
| Pontomedullary avulsion (with medulla oblongata crushed and partially transected) | Maximum (140212.6,8) | Expanding driver air bag |
| Laceration medial aspect cerebellar lobes | Severe (140474.4,6) | Expanding driver air bag |
| Diffuse basal subarachnoid hemorrhage (NFS) | Serious (140684.3,9) | Expanding driver air bag |
| Cervical spine fracture at C1 (NFS - with complete dislocation anteriorly) | Moderate (650216.2,6) | Expanding driver air bag |
| Abrasion tip of chin (1.5"x 2") | Minor (290202.1,4) | Expanding driver air bag |
| Abrasion left neck | Minor (390202.1,2) | Expanding driver air bag |
| Abrasion chest (6"x 2.5") (left clavicle area / midline chest) | Minor (490202.1,2) | Expanding driver air bag |

Source: autopsy report

Driver Pre-Existing Medical Condition

The driver suffered from a pre-existing medical condition named Klippel-Feil Syndrome, a rare degenerative disease of the cervical vertebrae that produced a natural fusion of her neck. The driver lived a normal life and was taking a co-worker home following her normal work shift. Klippel-Feil Syndrome is a rare medical disorder that makes the neck bones brittle. Classic symptoms include a short neck, low hair line, a restriction of neck motion and fusion of at least two of the seven cervical vertebrae. Fusion of the second and third cervical vertebrae is most common. The triad of classic symptoms are found in less than 50 percent of known cases. The most consistent finding among those afflicted by this disorder is limited cervical range of motion. Generally, flexion and extension are better preserved than side-bending and rotation. Original classification is based upon the extent of fusion but is not clinically useful. Although the etiology of this syndrome is unknown, what is known is that there is a failure of the normal segmentation of cervical somites during the third and

eighth weeks of fetal gestation. Individuals who suffer from this condition must always be aware of the associated anomalies that occur, as some hidden anomalies can be fatal. Minimally involved patients lead normal lives with only minor restrictions to avoid activities that place the neck at risk. Major neurologic sequela can include death or quadriplegia following minor trauma in high-risk patients. Treatment for Klippel-Feil is symptomatic and may include surgery to relieve cervical or craniocervical instability and constriction of the spinal cord, and to correct any associated abnormalities such as scoliosis. Physical therapy may also be useful.

Driver Kinematics

The 48 year old female driver of the 1998 Ford Ranger XLT was restrained by the available 3-point manual lap and shoulder belt system, and presumed to be seated in an upright posture with the seat track adjusted to the middle position. Belt usage was confirmed by the loading evidence documented on the D-ring, latch plate, and webbing of the driver restraint. Clothing worn by the driver included white socks, black gym shoes, blue trousers, and a black/red jacket.

At impact, the driver initiated a forward trajectory in response to the 12 o'clock impact force. Loading of the manual restraint resulted in abrasions of the left neck, shoulder, and (central) torso area, evidenced by the loading marks and deformation documented on the latch plate, D-ring, and webbing of the driver restraint. The driver's head and upper torso were displaced out-of-position forward by the elongated crash pulse prior to air bag deployment. The expanding driver air bag contacted the driver under the chin which resulted in abrasions of the chin and anterior neck. The continued expansion of the bag hyper-extended the neck resulting in an unspecified first cervical fracture with a complete dislocation anteriorly. Underlying trauma included a diffuse basal subarachnoid hemorrhage and a pontomedullary avulsion with the medulla oblongata crushed and partially transected. Cerebellar trauma involved a bilateral laceration to the medial aspect of the lobes. Although not codeable under NASS injury conventions, she also sustained a hemorrhage of the posterior paravertebral muscles of the neck and a focal hemorrhage on the tip of the tongue.

Following the crash, the passenger removed the driver through the left door and laid her on the ground adjacent to the final rest position of the vehicle. The passenger then observed the driver unconscious and not breathing, and placed her back into the driver seat of the vehicle. Police and fire department personnel arrived on-scene within minutes of the crash to find the driver (in the vehicle) unresponsive with no vital signs present. Although death was probably immediate, she was transported by ambulance to a local trauma center and pronounced deceased shortly after arrival. The internal injuries sustained may have been compounded by the unsafe removal of the driver by the passenger.

FRONT RIGHT PASSENGER DEMOGRAPHICS

| | |
|-----------------------|----------------------|
| Age/Sex: | 20 year old male |
| Height: | Unknown |
| Weight: | Unknown |
| Seat Track Position: | Mid-to-rear position |
| Manual Restraint Use: | None |

Usage Source: Vehicle inspection, police report
 Eyewear: Unknown
 Type of Medical Treatment: None

Front Right Passenger Injuries

| <i>Injury</i> | <i>Severity (AIS 90)</i> | <i>Injury Mechanism</i> |
|---------------|--------------------------|-------------------------|
| None | N/A | N/A |

Source: police

Front Right Passenger Kinematics

The unrestrained 20 year old male front right passenger of the 1998 Ford Ranger XLT was presumed to be seated in an upright posture with the seat track adjusted to the mid-to-rear position. The lack of belt usage was determined by the trajectory of the passenger relative to the absence of loading evidence on the passenger restraint system.

At impact, the front right passenger initiated a forward trajectory in response to the 12 o'clock impact force and loaded the knee bolster and deployed redesigned passenger air bag. Loading of the knee bolster was evidenced by the indentation documented on this component; however, no resulting injury was reported. Interaction with the deployed redesigned passenger air bag was confirmed by the blue fabric transfers documented across the right face and bottom portions of the air bag membrane. Although the passenger could not be located for the SCI interview, he was reported by police as uninjured in the collision. Following the crash, the front right passenger exited the vehicle under his own power through the right door and attended to the driver. The passenger subsequently summoned for help as police and fire department personnel arrived on-scene within minutes of the crash to find him waiting in the nearby discount store.

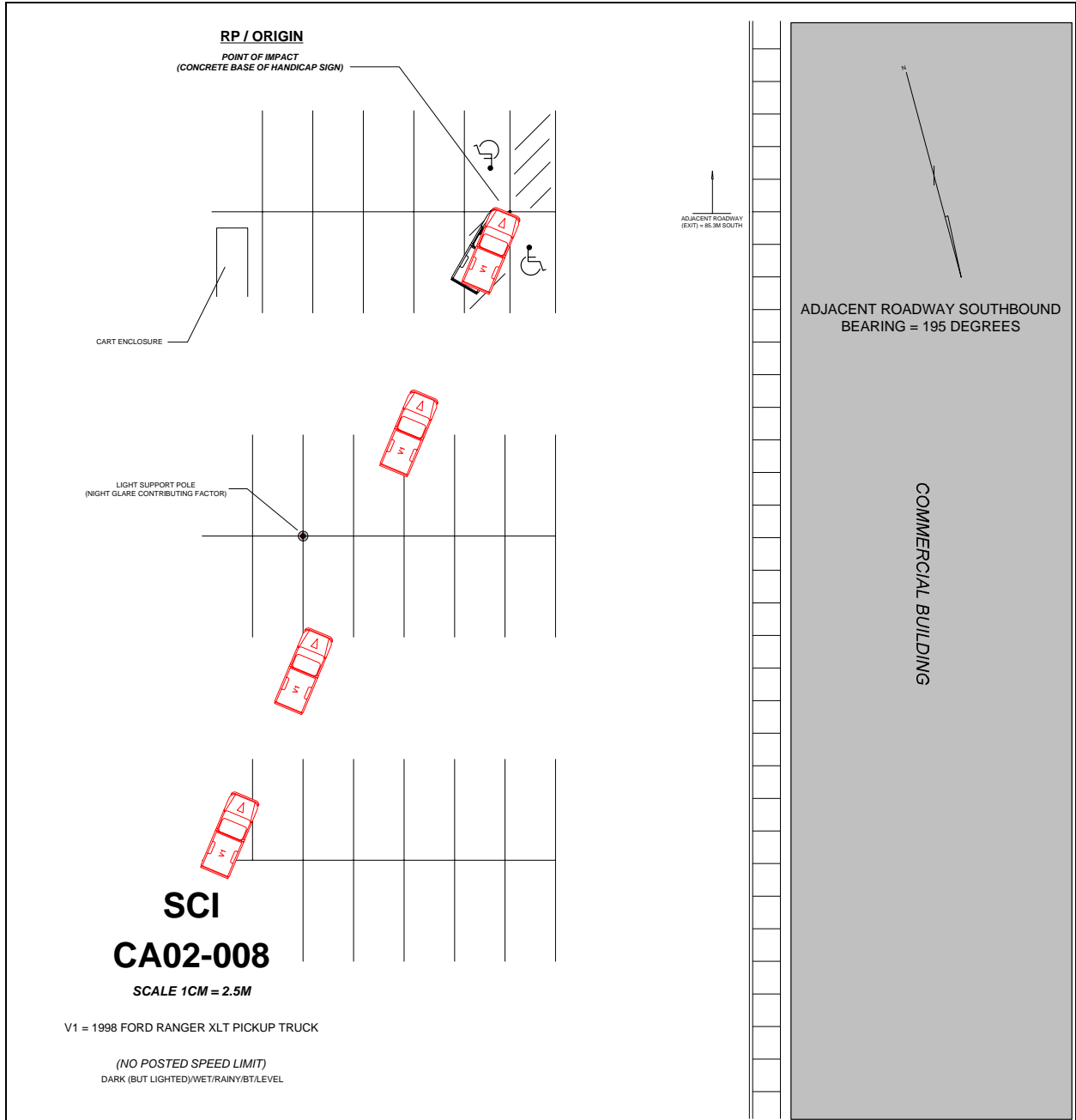


Figure 9 – Scene Schematic

