

**CRASH DATA RESEARCH CENTER**

Veridian  
Engineering Division  
Buffalo, New York 14225

**VERIDIAN ON-SITE CHILD PASSENGER FATALITY  
INVESTIGATION**

**VERIDIAN CASE NO. CA00-003**

**VEHICLE - 1996 FORD CONTOUR GL**

**LOCATION - STATE OF OHIO**

**CRASH DATE - JANUARY, 2000**

Contract No. DTNH22-94-D-07058

Prepared for:

U.S. Department of Transportation  
National Highway Traffic Safety Administration  
Washington, D.C. 20590

## **DISCLAIMER**

This document is disseminated under the sponsorship of the Department of Transportation in the interest of information exchange. The United States Government assumes no responsibility for the contents or use thereof.

The opinions, findings, and conclusions expressed in this publication are those of the authors and not necessarily those of the National Highway Traffic Safety Administration.

The crash investigation process is an inexact science which requires that physical evidence such as skid marks, vehicular damage measurements, and occupant contact points are coupled with the investigator's expert knowledge and experience of vehicle dynamics and occupant kinematics in order to determine the pre-crash, crash, and post-crash movements of involved vehicles and occupants.

Because each crash is a unique sequence of events, generalized conclusions cannot be made concerning the crashworthiness performance of the involved vehicle(s) or their safety systems.

## TECHNICAL REPORT STANDARD TITLE PAGE

1. <i>Report No.</i> CA00-003	2. <i>Government Accession No.</i>	3. <i>Recipient's Catalog No.</i>	
4. <i>Title and Subtitle</i> Veridian On-Site Child Passenger Fatality Investigation Vehicle - 1996 Ford Contour GL Location - State of Ohio		5. <i>Report Date:</i> May, 2001	
		6. <i>Performing Organization Code</i>	
7. <i>Author(s)</i> Crash Data Research Center		8. <i>Performing Organization Report No.</i>	
9. <i>Performing Organization Name and Address</i> Crash Data Research Center Veridian Engineering Division P.O. Box 400 Buffalo, New York 14225		10. <i>Work Unit No.</i> C01115.0263.(0000-0009)	
		11. <i>Contract or Grant No.</i> DTNH22-94-D-07058	
12. <i>Sponsoring Agency Name and Address</i> U.S. Department of Transportation National Highway Traffic Safety Administration Washington, D.C. 20590		13. <i>Type of Report and Period Covered</i> Technical Report Crash Date - January, 2000	
		14. <i>Sponsoring Agency Code</i>	
15. <i>Supplementary Notes</i> On-site investigation of a frontal collision (into a fixed object) that involved a 1996 Ford Contour GL 4-door sedan equipped with frontal air bags.			
16. <i>Abstract</i> <p>This on-site investigation focused on the injury mechanisms that caused the death of a 5 year old male front right passenger of a 1996 Ford Contour GL 4-door sedan. The Ford was equipped with frontal air bags for the driver and right passenger positions which deployed as a result of a frontal collision with a W-beam guardrail. The 25 year old female driver of the Ford Contour was operating the vehicle eastbound when she attempted to turn left (north) at a 3-leg intersection. As the driver initiated the left turn, she became distracted by the rear seated child occupants and continued a 125 degree constant radius turn towards the west pavement edge of the connector in a forward tracking mode. The vehicle's front wheels/tires made initial contact to the west barrier curb as the front left area subsequently impacted a W-beam guardrail resulting in minor damage. The front left corner area of the vehicle came to rest under the guardrail facing northwest.</p> <p>The 25 year old female driver of the 1996 Ford Contour was unrestrained (3-point manual lap and shoulder belt system available) and presumed to be seated out of position with her head and upper torso turned towards the rear seated occupants. At impact with the guardrail, she initiated a forward trajectory in response to the 12 o'clock impact force and loaded the deployed driver air bag and knee bolster. She was reported by police as uninjured. The 5 year old male front right child passenger was also unrestrained and initiated a forward trajectory in response to the initial barrier curb contact. At impact with the guardrail, he was out of position forward within the path of the expanding air bag which struck the child in the face resulting in multiple soft tissue injuries. He also sustained a multitude of brain trauma to include subdural and subarachnoid hemorrhages, contusions of the temporal lobes and extensive lacerations of the left frontal/parietal lobes. At this point, he was accelerated rearward into the front right seat back and came to rest on the floor of the vehicle. The child passenger was transported to a local hospital for treatment and expired the day following the crash. The rear left and right seating positions were occupied by a (unrestrained) 6 year old male and 3 year old female who, although reported by police as uninjured, were transported (along with the driver) to a local hospital for evaluation and released.</p>			
17. <i>Key Words</i> Top mount passenger air bag module Collision Deformation Classification (CDC): 12-FLEE-2 WinSMASH damage algorithm - Yielding object (out of scope) Diffuse axonal injury		18. <i>Distribution Statement</i> General Public	
19. <i>Security Classif. (of this report)</i> Unclassified	20. <i>Security Classif. (of this page)</i> Unclassified	21. <i>No. of Pages</i> 8	22. <i>Price</i>

## TABLE OF CONTENTS

BACKGROUND .....	1
SUMMARY	
Crash Site .....	1
Pre-Crash .....	2
Crash .....	2
Post-Crash .....	2
VEHICLE DATA .....	3
VEHICLE DAMAGE	
Exterior .....	3
Interior .....	3
MANUAL RESTRAINT SYSTEMS .....	4
SUPPLEMENTAL RESTRAINT SYSTEMS .....	4
DRIVER DEMOGRAPHICS .....	5
Driver Injuries .....	5
Driver Kinematics .....	5
FRONT RIGHT PASSENGER DEMOGRAPHICS .....	6
Front Right Passenger Injuries .....	6
Front Right Passenger Kinematics .....	7
REAR SEATED OCCUPANTS DEMOGRAPHICS / INJURIES .....	7
SCENE DIAGRAM .....	8

## VERIDIAN ON-SITE CHILD PASSENGER FATALITY INVESTIGATION

VERIDIAN CASE NO. CA00-003

VEHICLE - 1996 FORD CONTOUR GL

LOCATION - STATE OF OHIO

CRASH DATE - JANUARY, 2000

### ***BACKGROUND***

This on-site investigation focused on the injury mechanisms that caused the death of a 5 year old male front right passenger of a 1996 Ford Contour GL 4-door sedan. The Ford was equipped with frontal air bags for the driver and right passenger positions which deployed as a result of a frontal collision with a W-beam guardrail. The 25 year old female driver of the Ford Contour was operating the vehicle eastbound when she attempted to turn left (north) at a 3-leg intersection. As the driver initiated the left turn, she became distracted by the rear seated child occupants and continued a 125 degree constant radius turn towards the west pavement edge of the connector in a forward tracking mode. The vehicle's front wheels/tires made initial contact to the west barrier curb as the front left area subsequently impacted a W-beam guardrail resulting in minor damage. The front left corner area of the vehicle came to rest under the guardrail facing northwest.

The 25 year old female driver of the 1996 Ford Contour was unrestrained (3-point manual lap and shoulder belt system available) and presumed to be seated out of position with her head and upper torso turned towards the rear seated occupants. At impact with the guardrail, she initiated a forward trajectory in response to the 12 o'clock impact force and loaded the deployed driver air bag and knee bolster. She was reported by police as uninjured. The 5 year old male front right child passenger was also unrestrained and initiated a forward trajectory in response to the initial barrier curb contact. At impact with the guardrail, he was out of position forward within the path of the expanding air bag which struck the child in the face resulting in multiple soft tissue injuries. He also sustained a multitude of brain trauma to include subdural and subarachnoid hemorrhages, contusions of the temporal lobes and extensive lacerations of the left frontal/parietal lobes. At this point, he was accelerated rearward into the front right seat back and came to rest on the floor of the vehicle. The child passenger was transported to a local hospital for treatment and expired the day following the crash. The rear left and right seating positions were occupied by a (unrestrained) 6 year old male and 3 year old female who, although reported by police as uninjured, were transported (along with the driver) to a local hospital for evaluation and released.

The crash notification was provided to NHTSA on Monday, January 31, 2000 and immediately assigned to the Veridian SCI team as an on-site investigative effort. The on-site investigator departed on February 1 and conducted the investigation on Wednesday, February 2, 2000. Despite continued delays in acquisition of the police accident report (*and supporting driver information*), this investigation was closed May, 2001 in lieu of the SCI driver interview.

### ***SUMMARY***

#### **Crash Site**

This single vehicle crash occurred during the early morning hours of January, 2000. At the time of the crash, it was dark (roadway illuminated by overhead halogen lamps) with no adverse conditions as the roads were dry. The crash occurred off the west pavement edge of a straight and level five lane (one-

way) asphalt roadway (see **Figure 10 - page 8**). The urban roadway was bordered by barrier curbs with W-beam guardrails 0.7 meters (2.3 feet) off the west pavement edge and an industrial complex to the east. Traffic flow through the 3-leg intersection was controlled by an overhead traffic signal system with a posted speed limit of 56 km/h (35 mph).

### Pre-Crash

The 25 year old female driver of the 1996 Ford Contour GL was transporting her children to school and day care. She was operating the vehicle eastbound on the inboard lane of an urban two lane (one-way) local street on approach to a 3-leg intersection (**Figure 1**). She stopped at the signalized intersection and initiated a left turn to proceed northbound on the one-way connector. As the Ford entered the northbound lanes, the driver became distracted by the rear seated child occupants and continued a 125 degree constant radius turn towards the west pavement edge (**Figure 2**).



**Figure 1.** Eastbound approach for the 1996 Ford Contour GL.



**Figure 2.** Northwest approach into the guardrail impact.



**Figure 3.** Impacted guardrail.

### Crash

As the Ford exited the west pavement edge of the one-way connector, the front wheels/tires made initial contact to the barrier curb. The vehicle's trajectory was not altered by the curb as it continued 0.7 meters (2.3 feet) to impact with the W-beam guardrail (**Figure 3**). The front left area initially impacted the guardrail between the I-beam posts resulting in minor damage. The subsequent underride allowed the grille area to engage the horizontal component of the structure which produced a sufficient longitudinal deceleration to deploy the Ford's frontal air bag system. The minor severity crash probably resulted in a late deployment of the frontal air bag system due to the sheet metal engagement against the mid-point of the W-beam guardrail. Although the impact was classified as out of scope (yielding object), the WinSMASH damage algorithm computed a barrier equivalent velocity change of 14.0 km/h (8.7 mph) with a matching negative longitudinal component. The Collision Deformation Classification (CDC) for this impact to the Ford Contour was 12-FLEE-2 with a principal direction of force of 0 degrees. At this point, the vehicle was re-directed 18 degrees clockwise and came to rest with the front left corner area under the guardrail facing northwest.

### Post-Crash

Following the crash, the driver of the Ford Contour retrieved the front right passenger from the right floor and placed the child on her lap until police/rescue personnel arrived on-scene within six minutes of the crash. The driver and rear seated child occupants exited the vehicle with some assistance while the front right child passenger was removed from the vehicle by paramedics in an unconscious state.

Treatment was rendered at the scene by fire department personnel and emergency medical technicians (EMT). The 5 year old male front right passenger was transported to a local hospital for treatment and expired the day after the crash. The driver and rear seated occupants were reported by police as uninjured, but were transported to a local hospital for evaluation and released. Although towed from the scene, the damage sustained did not inhibit the vehicle from being driven from the scene.

### **VEHICLE DATA**

The 1996 Ford Contour GL was manufactured on 6/96 and identified by the vehicle identification number (VIN): 1FALP6533TK (production number deleted). The driver was reported by police as the owner of the vehicle. The vehicle was a 4-door sedan equipped with front wheel drive and a 2.0 liter, 4 cylinder engine. The Ford was also equipped with power windows, door locks, steering and front disc/rear drum brakes. At the time of the crash, the odometer had recorded 107,982 km (67,099 miles). The seating was configured with front bucket seats and a rear bench. Per a police request, the interview had not been obtained, therefore, previous crashes or maintenance on the Ford's air bag system were unknown. No cell phone was present or in use at the time of the collision.

### **VEHICLE DAMAGE**

#### **Exterior**

The Ford sustained minor frontal damage as a result of the impact with the guardrail (**Figure 4**). The direct contact damage began at the front left bumper corner and extended 42.0 cm (16.5 in) inboard. The combined direct and induced damage length (Field L) measured 144.0 cm (56.7 in). Although no crush was identified at any of the six *bumper level* measurements, a secondary profile was obtained at the level of the mid-radiator [11.0 cm (4.3 in) above the level of the bumper] to capture the underride damage resulting in an *averaged* profile of: C1= 13.0 cm (5.1 in), C2= 7.0 cm (2.8 in), C3= 0 cm, C4= 0 cm, C5= 0 cm, C6= 0 cm. The left portion of the bumper fascia fractured and separated from the reinforcement bar during the collision sequence. The left headlamp assembly shattered with minimal hood displacement noted from the guardrail underride (**Figure 5**). The left fender was deformed slightly rearward with 75.0 cm (29.5 in) of direct contact damage documented rearward along the side surface of the vehicle. The right front wheel was deflated (not restricted) with no notable rim damage from the barrier curb contact. A film of road salt was noted over the surface of the vehicle. The windshield was undamaged.



**Figure 4. Frontal damage to the 1996 Ford Contour GL.**



**Figure 5. Close-up view of the damaged area.**

#### **Interior**

Interior damage to the Ford identified through the vehicle inspection was moderate and was attributed to occupant contact. Multiple scuff marks were documented on the left knee bolster (rigid plastic type) which was also fractured and heavily scratched. A hair strand and scuff mark were found on the driver's sunvisor. A scratch mark was identified on the center instrument panel area just above the climate controls. Blood spattering was noted along the right roof side rail area and front right seat


cushion. A multitude of contacts were documented to the rear portion of the front seat backs from rear occupant loading. This contact evidence included teeth marks, scuff marks and minor indentations. No column compression or loading to the steering wheel rim was identified (tilt column set to the full down position). No intrusion of interior components were found in the vehicle.

### ***MANUAL RESTRAINT SYSTEMS***

The interior of the Ford Contour GL consisted of a five passenger seating configuration with front bucket and a rear bench seat which accommodates three individual seating positions. There was no loading evidence on the belt systems and the systems yielded minimal routine usage indicators for the recorded mileage. The driver 3-point manual lap and shoulder belt system consisted of a continuous loop belt webbing with a sliding latchplate and a dual mode retractor (inertial lock/belt sensitive). The front right 3-point manual lap and shoulder belt system consisted of a continuous loop belt webbing with a sliding latchplate and a retractor equipped with an inertial and switchable lock mechanism. The rear outboard seated positions were equipped with 3-point manual lap and shoulder belt systems which consisted of continuous loop belt webbings with sliding latchplates that retracted into inertial sensitive and switchable locking retractors. The rear center seating position was equipped with a 2-point manual lap belt system.

### ***SUPPLEMENTAL RESTRAINT SYSTEMS***

The Ford Contour was equipped with frontal air bags for the driver and right passenger positions. The air bags deployed as a result of the crash. The driver air bag was housed in the center of the steering wheel with a horizontally oriented flap tear seam (H-configuration). The flaps were asymmetrical in shape as the upper flap measured 26.0 cm (10.2 in) in width along the upper portion, 19.0 cm (7.5 in) along the lower portion and 10.0 cm (3.9 in) in height. The lower flap measured 19.0 cm (7.5 in) in width along the upper portion, 21.0 cm (8.3 in) along the lower portion and 7.0 cm (2.8 in) in height. Although no contact evidence was identified on the exterior surface of the module cover flaps, eye makeup was documented to the upper (centered) portion of the air bag along with facial makeup to the right (centered) portion. The diameter of the driver air bag measured 51.0 cm (20.1 in) in its deflated state (**Figure 6**). The bag was tethered by two internal straps and vented by two ports located at the 11 o'clock and 1 o'clock sectors on the rear aspect of the air bag.



**Figure 6. 1996 Ford Contour GL deployed driver air bag.**

The front right passenger air bag deployed from the right top instrument panel area with a single cover flap design hinged at the forward aspect. The sheet metal reinforced flap opened in an upward direction towards the windshield. The cover flap was irregular in shape and measured 37.0 cm (14.6 in) in width along the rear aspect of the flap and 52.0 cm (20.5 in) along the forward aspect. The flap measured 33.0 cm (13.0 in) in height along the left edge of the flap and 21.0 cm (8.3 in) along the right edge. No contact evidence was found on the exterior surface of the module cover flap. The passenger air bag measured 73.5 cm (28.9 in) in width and 53.5 cm (21.1 in) in height in its deflated state (**Figure 7**). Although no contact evidence was identified on the face of the air bag, blood transfers were documented to the bottom portion. These transfers were attributed to the child passenger's chin laceration as he laid against the deflated air bag following the crash (**Figure 8**). His interaction with the



air bag during the collision sequence produced two distinct scuff marks on the right mid-windshield area from the upper portion of the air bag. In addition, small abrasions were noted to the bottom portion of the air bag from intra-flap snagging during bag expansion. The bag was tethered by two internal straps sewn to the top seam and vented by one port located at the 10 o'clock sector on the inboard aspect of the air bag.



Figure 7. 1996 Ford Contour GL deployed passenger air bag.



Figure 8. Air bag scuffs to the right windshield area and blood stains to the bottom portion of the passenger air bag.

### **DRIVER DEMOGRAPHICS**

Age/Sex:	25 year old female
Height:	155 cm (61 in)
Weight:	59 kg (130 lb)
Seat Track Position:	Middle position - 12.0 cm (4.7 in) aft of the full forward position, 10.0 cm (3.9 in) forward of the full rearward position
Manual Restraint Use:	None
Usage Source:	Vehicle inspection, police interview
Eyewear:	Unknown
Type of Medical Treatment:	Transported to a local hospital for evaluation and released

### **Driver Injuries**

<i>Injury</i>	<i>Severity (AIS 90)</i>	<i>Injury Mechanism</i>
None reported	N/A	N/A

### **Driver Kinematics**

The unrestrained 25 year old female driver of the 1996 Ford Contour GL was presumed to be seated out of position with her head and upper torso turned towards the rear seated child occupants. Lack of restraint usage was confirmed by the absence of loading evidence to the available 3-point manual lap and shoulder belt system and contact points within the vehicle. The seat back support was reclined to 23 degrees from vertical with the seat track adjusted 12.0 cm (4.7 in) aft of the forward most position.

At impact with the guardrail, the driver initiated a forward trajectory in response to the 12 o'clock impact force and loaded the deployed driver air bag and knee bolster, evidenced by the makeup transfers documented to the air bag and scuff/scratch marks documented to the bolster. Following the collision, she retrieved the injured front right passenger from the right floor and placed the child on her lap until police/rescue arrived on-scene within six minutes of the crash. She was subsequently assisted from the vehicle by rescue personnel. Although reported by police as uninjured, the driver was transported by ambulance to a local hospital for evaluation and released.

## ***FRONT RIGHT PASSENGER DEMOGRAPHICS***

Age/Sex: 5 year old male  
Height: 117 cm (46 in)  
Weight: 18 kg (40 lb)  
Seat Track Position: Full rearward position  
Manual Restraint Use: None  
Usage Source: Vehicle inspection, police interview  
Eyeware: None  
Type of Medical Treatment: Transported to a local hospital and admitted (expired the next day)

### **Front Right Passenger Injuries**

<b><i>Injury</i></b>	<b><i>Severity (AIS 90)</i></b>	<b><i>Injury Mechanism</i></b>
*Diffuse axonal injury of mid-brain (pons)	Critical (140206.5,8)	Expanding front right air bag
*Parenchymal hemorrhage mid-brain	Critical (140210.5,8)	Expanding front right air bag
*Hemorrhagic contusion right hippocampus	Critical (140204.5,8)	Expanding front right air bag
*Subdural hemorrhage-cerebrum (anterior)	Critical (140654.5,3)	Expanding front right air bag
*Subdural hemorrhage-cerebrum (posterior)	Severe (140442.4,6)	Expanding front right air bag
*Extensive laceration/hemorrhage left frontal/parietal lobes	Severe (140688.4,2)	Expanding front right air bag
*Diffuse subarachnoid hemorrhage-cerebrum	Serious (140684.3,9)	Expanding front right air bag
*Contusion inferior temporal lobe (bilateral)	Serious (140620.3,3)	Expanding front right air bag
*Diffuse scalp hemorrhage (anterior/"intense")	Minor (190402.1,5)	Expanding front right air bag
*Hemorrhage right conjunctivae	Minor (240416.1,1)	Expanding front right air bag
*Hemorrhage left conjunctivae	Minor (240416.1,2)	Expanding front right air bag
*Contusion right orbit (3x1.5cm)	Minor (297402.1,1)	Expanding front right air bag
*Contusion left orbit (3x1.5cm)	Minor (297402.1,2)	Expanding front right air bag
*Mucosal rupture	Minor (251090.1,4)	Expanding front right air bag
*Laceration buccal surface lower lip (gum)	Minor (243204.1,8)	Expanding front right air bag
*Laceration chin (5cm)	Minor (290602.1,8)	Expanding front right air bag
*Abrasion left face (multiple) includes: Abrasion lateral to left eye (2x2cm) Abrasion left cheek-above lip (2x2cm)	Minor (290202.1,2)	Expanding front right air bag
*Abrasion left lower chin/lower lip (2x2.5cm)	Minor (290202.1,8)	Expanding front right air bag

\* Source - autopsy report

### **Front Right Passenger Kinematics**

The unrestrained 5 year old male passenger of the 1996 Ford Contour GL was presumed to be seated in an upright posture with the seat track adjusted to the full rearward position (**Figure 9**). The length of the seat cushion and short femur length of an average child this age probably necessitated a more comfortable forward position in the seat with the upper body more upright. Lack of restraint usage was determined by the trajectory of the child and contact points within the vehicle. In addition, there was no loading evidence on the belt system and the system yielded minimal routine usage indicators for the recorded mileage. He was wearing a blue winter parka which was later found to be stained with blood and cut by paramedics during post-crash treatment at the scene.



**Figure 9. Interior view of the front right passenger space.**

The child passenger was displaced out of position forward due to the initial barrier curb contact. At impact with the guardrail, the child was forward within a close proximity to the passenger air bag module. Although he was not struck by the module cover, the expanding air bag membrane struck him in the face resulting in multiple soft tissue injuries to include a 5.1 cm (2.0 in) chin laceration, contusions of the anterior scalp and orbits, abrasions of the left cheek, chin and lower lip. Associated underlying brain trauma included subdural/subarachnoid hemorrhages of the cerebrum, contusions of the temporal lobes, diffuse axonal injury/parenchymal hemorrhages of the mid-brain and extensive lacerations of the left frontal/parietal lobes. The minor severity crash probably resulted in a late deployment of the frontal air bag system due to the sheet metal engagement against the mid-point of the W-beam guardrail. This would have allowed the child to move further forward from his rear track position prior to deployment. In addition, his interaction with the expanding air bag re-directed the proper deployment path of the membrane and produced the noted scuff marks to the right windshield area. At this point, the expanding air bag membrane propelled the child rearward into the front right seat back.

The child came to rest across the front right floor of the vehicle (head oriented towards the gearshift) on or under the deflated air bag as evidenced by the blood stains identified on the bottom portion of the bag. The driver subsequently placed the unconscious child passenger on her lap until rescue personnel arrived. The child was transported to a local hospital and admitted for treatment. Treatment at the hospital included placement of an ICP to monitor cranial pressure and subsequent removal of a 10.2 cm (4.0 in) section of skull to further alleviate extensive brain swelling. The child was hospitalized for one day before succumbing to his injuries.

### ***REAR SEATED OCCUPANTS DEMOGRAPHICS / INJURIES***

The unrestrained 6 year old male passenger of the 1996 Ford Contour GL was presumed to be seated in an upright posture in the rear left position. The lack of restraint usage was determined by the absence of loading evidence on the available 3-point manual lap and shoulder belt system and contact points within the vehicle. At impact with the guardrail, he initiated a forward trajectory in response to the 12 o'clock impact force and loaded the front left seat back, evidenced by the teeth and scuff marks documented to this component. Although reported by police as uninjured, the child occupant was transported by ambulance to a local hospital for evaluation and released.

The 3 year old female passenger of the 1996 Ford Contour GL was presumed to be seated in an upright posture in the rear right position. The lack of restraint usage was determined by the absence of loading evidence on the available 3-point manual lap and shoulder belt system and contact points within the vehicle. At impact with the guardrail, she initiated a forward trajectory in response to the 12 o'clock impact force and loaded the front right seat back, evidenced by the hair strands and scuff marks documented to this component. Although reported by police as uninjured, the child occupant was transported by ambulance to a local hospital for evaluation and released.

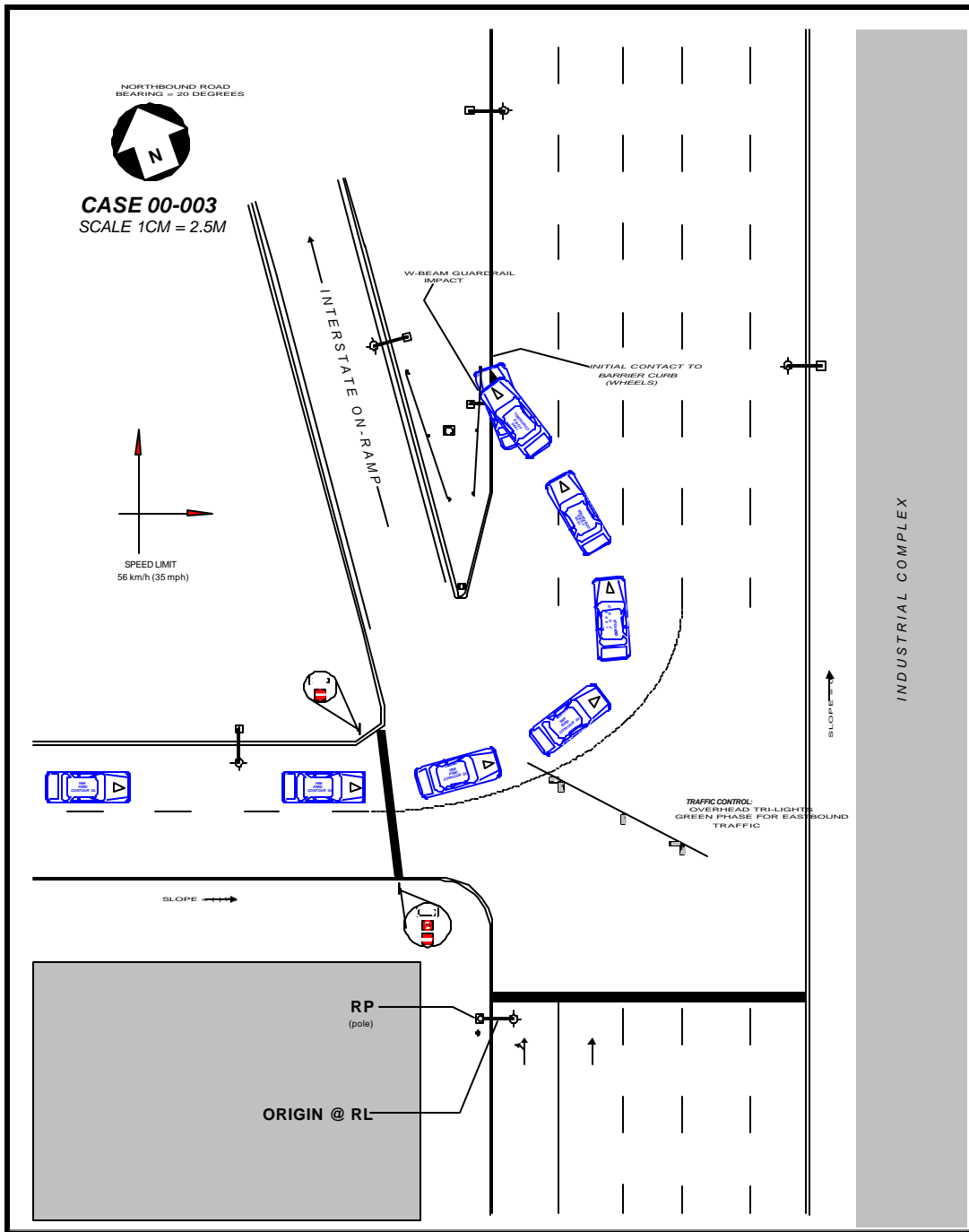


Figure 10. Scene Diagram